Chapter 14

LEPROSY

JAMES W. STEGER, M.D.* AND TERRY L. BARRETT, M.D.†

INTRODUCTION

HISTORY
- **Leprosy in Antiquity**
- **Leprosy in Medieval and Renaissance Europe**
- **Modern Advances in the Study of Leprosy**
- **Leprosy in the U.S. Military**

EPIDEMIOLOGY

MICROBIOLOGY
- **Natural Reservoirs and Laboratory Transmission**
- **The Cell Wall**
- **Molecular Biology and Genetics**

IMMUNOLOGY
- **Humoral Immunity**
- **Cell-Mediated Immunity**
- **The Lepromin Test**

LABORATORY DIAGNOSIS
- **The Slit-Skin Examination Technique**
- **Bacterial Index**
- **Morphologic Index**
- **Cutaneous Nerve Biopsy**
- **Serologic Assays**

CLINICAL AND HISTOLOGICAL DIAGNOSTIC CRITERIA

TREATMENT
- **Paucibacillary Leprosy**
- **Multibacillary Leprosy**
- **The Most Potent Antileprosy Drugs**
- **Drug Resistance**
- **Microbial Persistence**
- **Promising New Drugs**

COMPLICATIONS: THE REACTIONAL STATES
- **Reversal Reaction**
- **Erythema Nodosum Leprosum**
- **Downgrading Reaction**
- **Lucio's Phenomenon**

VACCINATION

LEPROSY AND ACQUIRED IMMUNODEFICIENCY SYNDROME

SUMMARY

*Captain, Medical Corps, U.S. Navy; Head, Dermatology Clinic, Naval Hospital, San Diego, California 92134-5000
†Captain, Medical Corps, U.S. Navy; Pathology and Dermatopathology Consultant, Naval Hospital, San Diego, California 92134-5000

INTRODUCTION

Leprosy (also called Hansen's disease) is an infectious disease caused by *Mycobacterium leprae* that affects principally the skin, the peripheral nervous system, and certain other organs. Depending on their immune status, patients with leprosy may present with a wide range of cutaneous and neurological signs and symptoms. These signs and symptoms have been grouped together to delineate leprosy into a spectrum of clinical forms or stages whose complications and therapies differ from one another. Thus, it is important at the outset to be aware of these clinical forms.

The simplest classification scheme is based on the relative immune status of the host. The form found in hosts with the highest immunity is known as *tuberculoid* leprosy; with the lowest immunity, *lepromatous* leprosy; and with intermediate immunity, *borderline* leprosy. Unfortunately, there are unstable transition forms between these groupings and very stable polar forms at the high and low ends of the immune state. Consequently, leprosy is now subdivided into seven stages of disease, arranged from lowest to highest immune status of the host:

- lepromatous lepromatous polar type (LLp),
- lepromatous lepromatous subpolar type (LLs),
- borderline lepromatous type (BL),
- borderline borderline type (BB),
- borderline tuberculoid type (BT),
- tuberculoid tuberculoid subpolar type (TTs), and
- tuberculoid tuberculoid polar type (TTp).

The polar forms never change to any other form, whereas all the remaining forms can change from one form to the next. These transitional forms arise through fluctuations in the host's immune system. Transitions from a higher to a lower immune status are reactional states known as *downgrading* reactions, the converse as *reversal* reactions. Both types of reactional states complicate therapy. An infected patient whose clinical presentation (usually a hypopigmented patch) is not diagnostic is said to have *indeterminate* leprosy. In time, one of four such patients will develop lesions characteristic of one of the other forms of leprosy; the other three patients will clear spontaneously. Where no skin lesions are present but nerve damage has occurred, the disease is designated *primary neuritic* leprosy.

Although it was epidemic during the Middle Ages, today leprosy is acquired primarily by susceptible individuals and then only through prolonged contact (months to years) with infected individuals. In general, oriental and black people tend to be much more susceptible to the disease than white people.

Individuals infected with the lepromatous forms of the disease, whose immune status is low and who harbor enormous bacterial loads, particularly in their nasal mucosa, are the most dangerous sources of infection to susceptible troops. Therefore, military interest centers chiefly on the chance encounter with such patients in those countries where the prevalence of lepromatous leprosy is high, and on those troops from susceptible racial backgrounds. Because even mention of the word leprosy may elicit irrational and hysterical responses based on fear and ignorance, it behooves unit commanders and medical personnel to be well informed on the low infectiousness of the disease and to educate their troops accordingly.

HISTORY

Perhaps because leprosy is of ancient origin and was feared and loathed, historical records abound that describe diseases that (*a*) are strikingly similar to the disease we know as leprosy, albeit by different names, and (*b*) diseases that may have been called leprosy then but clearly are not the disease we know today. The following brief account attempts to tease apart these sometimes intertwined historical trails. For example, from the time of Hammurabi (1958–1916 BC), the King of Babel on the Euphrates, a disease was known that resembles what we call leprosy, and was recognized as being related to human association.[1] On the other hand, it seems clear that the disease called leprosy in the Bible could not have been the disease we call leprosy today.

Unless otherwise specified, the following general historical review of leprosy is translated from the German and adapted for this chapter (by JWS) from Klingmüeller's comprehensive history of lep-

rosy,[1] which was published in 1930 and is difficult to obtain in the United States.

The review of leprosy in military history prior to the Vietnam conflict has been abridged and adapted from the official history of the U.S. Army Medical Department in World War II.[2] This unique source documents the military significance of and experience with leprosy through World War II.

Leprosy in Antiquity

Egypt

Egypt is generally agreed to be the land where the earliest history of leprosy can be found. In the Berlin Papyrus from the time of Rhamses II (1333 BC) is a letter concerning the treatment of leprosy, which concerns the time of Pharaoh Sapti 5th who, according to Brugsch, lived about 4266 BC. The German dermatologist, Iwan Bloch, a student of Unna, has determined that the character "aat" in the Ebers Papyrus was a designation for leprosy—on account of hyperaesthesia, hair loss, and sudden collapse of the nose. (However, his findings were contradicted by Richter.) Around 1700 BC, the Hyskos, a seminomadic tribe out of Asia Minor, invaded Egypt, resulting in a mixing of Egyptians and Asians. This may be important as it is believed that leprosy arose in Asia.[1]

The Exodus of the Jews from Egypt occurred around 1440 BC under Amenhotep II, or in the 16th century under Thothmes IV (according to Conder). At the time of the Exodus, according to the Egyptian historian Manetho (circa 300 BC), about 80,000 Jews were affected with leprosy. However, they lived in Goshen on the east side of the Nile, and did not mix with the Egyptians to any great extent—and later departed for Canaan. In the 6th to 5th centuries BC, the Persians ruled Egypt, resulting in a great mixing of populations. Around 250 BC, the Septuigent, a Greek translation of the Hebrew Bible, was started by Hebrew scholars. They translated the Hebrew word *Zaraath* as Lepra, which, according to the Greek physician Hippocrates, was the name given to a scaly skin condition. Hopes that the skulls and bones of Egyptian mummies might reveal earlier evidence of leprosy have not been fulfilled; the earliest pathological changes suggestive of leprosy date from the 2nd century BC.[1]

In the Bible

t[‘r"Ÿx;, pronounced "tzah-rah-AHT," and usually transliterated as *zaraath*, is the Hebrew word found in the *Tanakh* (the Hebrew Bible, ie, Old Testament) that has traditionally been translated as "leprosy" in many editions of the Bible. In the Torah, as described in Leviticus, the Third Book of Moses, t[‘r"Ÿx; is (*a*) diagnosed by the priests and (*b*) associated with periods of quarantine, both suggesting that its presence is due to the wrath of God. This may be the origin of the irrational horror of the disease and the ostracism of afflicted individuals.

The clinical characteristics of t[‘r"Ÿx; as revealed in the Scriptures of Leviticus 13 include the triad of (1) a white or shiny patch in the skin, (2) depression of the skin [*also translated as deeper than the skin—JWS*], and (3) whitening of the hair. However, the account seems not to have mentioned hyperpigmentation, alteration in cutaneous sensation, facial disfigurement, or loss of eyebrows; and no blindness, muscular palsies, or hideous mutilations.

Lastly, and most interestingly: if the condition involves the entire cutaneous surface, the individual is to be pronounced "clean" (ie, not infectious), and no longer to be excluded from the community:

> If t[‘r"Ÿx; breaks out all over his skin and, so far as the priest can see, it covers all the skin of the infected person from head to foot, the priest is to examine him, and if the t[‘r"Ÿx; has covered his whole body, he shall pronounce that person clean.[3] [*Hebrew word* t[‘r"Ÿx; *not translated—JWS*]

Obviously, then, t[‘r"Ÿx; and leprosy cannot be equated. No leper with disease from head to toe would ever be clean according to Jewish law.

Interestingly, in the New Testament when Jesus encountered the man full of "leprosy" in the Gospel According to Luke, Chapter 5, and cleansed him of his leprosy, Jesus told him to go and show himself to the priest and make an offering for his cleansing, just as Moses had commanded regarding t[‘r"Ÿx;. [*Similarly, for the 10 lepers in the Gospel According to Luke, Chapter 17—JWS*] Consequently, it is obvious that the leprosy of the Bible is something quite different from Hansen's disease. In fact, there is no known dermatologic disease that incorporates all its features. Modern interpreters consider the term to represent a variety of infections or skin inflammations. In Biblical context, it appears to be a sign of God's displeasure.[4]

Persia

Concerning Persia in the 6th century BC, Herodotus (484?–425? BC) writes in *The History*, Book 1, 138:

> If a citizen has "leprae" or a white rash, he should not go into the city or into a group of people, but becomes a stranger, and is to be driven out of the land.[1(p6)]

It has not been shown that the conquests of Darius I (521–486 BC) and Xerxes I (486–465 BC) spread leprosy to the western parts of Asia minor, the Grecian Islands, or Greece proper, even though Xerxes' troops and logistic supports numbered over 1 million individuals.[1]

Greece

The contact of the Greeks with the eastern populaces through the Persian wars, and especially through the far-reaching (to India) campaigns of Alexander the Great (336–323 BC) and the subsequent campaigns of Diadochen (323–301 BC), surely have contributed to the spread of leprosy. The Greek writer Ktesias from Persica described in the 5th century BC that leprosy had "ruled" in Persia.[1]

The Phoenicians operated as agents between Asia and Europe in the spread of leprosy. In the 7th through the 6th centuries BC, they carried their trade from Asia to the French and English coasts.

In Greece up to the time of Hippocrates (460–377 BC), leprosy was essentially unknown. The term "leprae" was used to describe scaly rashes more on the order of psoriasis or eczema. It appears that Aristotle (384–322 BC), under the name Satyriasis, possibly described true leprosy (*de generat. animal* IV, 3).[1] The earliest description of a disease that is unmistakably leprosy was by Aretaeus, in Greece, about AD 150. He called the disease elephantiasis.[5] Plutarch (AD 46?–120?) (*Sympos* VIII, *Qu* IX) quoted the Greek physician Philon as stating that none of the ancient Greek physicians had given any information about elephantiasis. In Persian references and through Persian military campaigns, leprosy could have been transmitted from the peoples of Persia, Syria, or Phoenicia to Greece.[1]

The oldest Alexandrian physician (3rd century), Galen, brings us a detailed description of leprosy and notes the following symptoms (Galen, *introductio cap*. XIII)[1]:

- the superficial changes in the skin from inflammation and ulcers/abscess/boils as leprosy,
- the thickening of the joints and other parts of the body as elephantiasis,
- the changes on the face as "leontiasis,"
- the loss of hair as ophiasis and alopecia, and
- mutilations.

The Roman Empire

It was during the time of Asklepiades, a contemporary of Pompey (106–48 BC), according to Plutarch (AD 46?–120?), (*Sympos*. VIII, 9), that leprosy first made its appearance in Italy. However, it appeared only rarely in the 1st century BC in Rome. But it was at this time that the nomenclature became clear: what one called lepra (Greek) in the Hippocratic sense was a scaly skin disease, and what one called elephantiasis (Greek) was true leprosy in today's sense. In 95 BC Lucretius wrote of an "elephant disease" (elephas morbus) that raged on the banks of the Nile. The notion that this was leprosy is rendered more probable by a passage in Celsus concerning "elephantiasis." Around the time of Christ, characteristic descriptions of leprosy are found. Aulus Cornelius Celsus, a contemporary of Tiberius (AD 14–37) wrote:

> Totally unknown in Italy, but very frequent in a few other lands is the disease which the Greeks call elephantiasis. It is heard to be chronic. The whole body is so afflicted with it, that even the bones are afflicted. The surface of the body shows many spots and ulcers/abscesses which are closest to red in color, but progressively assume a black color. The skin is thick in many places, in other areas it is thin, in a few hard, in a few soft, and somewhat rough from scaling, thereby the body appearing emaciated, while, on the contrary, the face, the lower extremities and the feet are swollen. Where the disease has been present for a long time, there is a disappearance of the fingers of the hands and the toes of the feet in the swelling, and a slight fever occurs all of which causes great sorrow.[1(p8)]

At a later time, Cajus Plinius Secundus (AD 23–39) in *Natural History* XXVI, 5 and XX, 14 writes: "We have already said that the elephantiasis had not arrived in Italy before the time of Pompey the Great."[1(p8)] Caelius Aurelianus (*morb. chron* IV, cap 1), who lived in Rome, was a founder of the method school, a contemporary of Pliny the Elder, and the first to extensively deal with the treatment of lepra. Philumenus (circa AD 150) extensively described the treatment of elephantiasis: baths of albula and nepete; mineral springs in Macedonia, Thrace, Crete, and Anchialus; and steam baths followed by cold sulfur application or alum baths, all of which shorten the healing, "if the skin is as repulsive as that of a snake!"[1(p8)]

In the 2nd century the campaigns of the Roman emperors, especially towards Asia (eg, Trajan against the Parthians in AD 114–116, his campaign to the Tigris River and the Persian Gulf) resulted in the greater possibility of a spread of leprosy to Italy and Europe. And so it appears that in this time, courtesy of the Roman legions' traveling, leprosy reached Spain, France, Germany, and especially Lombardy, and continued to spread throughout the Roman Empire.[1]

India

A larger outbreak of leprosy appeared to have occurred in India. In the 14th and 15th centuries AD, the Rig Veda sanhita used the term *kushtah* for a disease that was undoubtedly leprosy, a term that is still used today in India for the disease. In the interpretations of the text, there is the suggestion of references back to the 7th century AD. In the 4th century AD in the canonical texts, similar writings are found. In the Ayurveda (2000–500 BC), various treatments—including chaulmoogra oil—were suggested for the treatment of leprouslike conditions. More recent investigations have found that *kushtah* was first described about 600 BC in the Susruth Samhita. Treatment at that time was also undertaken with chaulmoogra oil, a folk remedy that has had continued use up to the present day.[5]

China

Leprosy has definitely been present in China for at least 2,000 years. The first reported incidence of leprosy in China was 1100 BC, and 200 to 300 years before Confucius (5th century BC), leprosy was thought to be a punishment for sins. In the last book of medical science of Su-wen, written toward the end of the Chon dynasty (1130–250 BC), the disease *lei-fon* is described as having (1) loss of sensation, (2) destruction of the nasal structures, and (3) discoloration, ulcers, or abscesses of the skin.[6]

Recently, an ancient book from the Ch'in dynasty (221–206 BC), the *Bamboo Book*, has been excavated from the tomb of magistrate Hsi in Yun Meng, Hupeh. In it, leprosy is well described:

> Cha went to see Bing and said to Bing, "I think you have Leprosy (Li)." Bing replied, "At age three I was sick, my eyebrows were swollen and nobody knew what the sickness was. I was directed to see a doctor, Ting. The doctor said, you don't have eyebrows because they are rootless. Your nostril is destroyed; you cannot sneeze on irritation; your legs are halt because one of them burst, and your hands have no hair." He asked Bing to shout and the voice was hoarse. That is leprosy.[6(p291)]

This historically significant document, having been excavated and dated, represents original material rather than a redacted version from subsequent generations.[6]

Chang Chung-ching (AD 150–219), often referred to as the Hippocrates of China, wrote in his classic book, *Shang Han Lun* (*Essay on Typhoid*) that a person having leprosy has very little hair and eyebrows left, and his body is full of sores that have a fishy and stinking smell.[6]

In Chou-hau-hong, during the Chin Dynasty (AD 265–419), a disease with the name of lai-ping, whose manifestations included a loss of sensation and formication was described by Kwo-Hon (AD 281–361).[1] He described a second man whose leprosy was cured with pine cones. In another work, Kwo-Hon describes a military official named Tsui Yen who was suddenly afflicted with leprosy:

> His eyes grew dim, he could not distinguish either objects or men. The eyebrows and hair fell off, the nasal bridge dropped and the skin was covered with sores.[6(p294)]

The man was later cured with saponin and rhubarb solution. Pine cones and saponin are still in the Chinese pharmacopoeia for leprosy and ulcers, respectively.[6]

Later in China, Pin-yüan-hou-lun (AD 589–617), detailed the signs of leprosy so clearly that no confusion with any other disease is possible: anesthesia, paresthesia, pains in the joints, insensibility to needle stick, anhidrosis, loss of fingers, cutaneous nodules, loss of the eyebrows, and roughness of the voice.[1]

Chaulmoogra oil, obtained from the seed of a coconut-shaped fruit of the Hydnocarpus tree, native to Cambodia, was probably imported into China in the Southern Sung period (1127–1278). Its value in the treatment of leprosy was well known, but required careful monitoring for side effects since it was poisonous to the blood and the eyes. One herbalist gives directions for the preparation of the oil as follows:

> Take three catties of the seeds, discard those that have turned yellow, remove the husks and grind into a fine powder. Pack in earthenware jar and seal up tightly. Put the jar into a pot of boiling water and seal the pot so that no steam can escape. Boil until the oil assumes a black and tar-like appearance. It is administered in the following way:
>
> | | |
> |---|---|
> | Chaulmoogra oil | 1 ounce |
> | Saphoro flavescens | 3 ounces |
>
> Mix into a paste with wine and make into pills the size of a stercula seed. *Sig*: Take 50 pills with hot wine before meals.[6(p301)]

Japan

Written about the year AD 702 in a place called Reinogige, in the Commentary of Taiho-rei, the second-oldest Japanese law book, the following comments are found about leprosy:

> There is loss of the eyebrows, destruction of the nasal structures, hoarseness, mutilation of the joints; one must not share a bed with such a diseased person, because the disease can be communicated to the next person.[1(p 4)]

Leprosy was apparently endemic in Japan for 1,000 years. In AD 1554, the Portuguese Louis Almeida established a hospital in Funai, Japan, for syphilis and leprosy. The oldest leprosy colony, however, was apparently established in Nara, near Kyoto, perhaps going back to the time of Emperor Gwyo (AD 718–740), who, according to legend, washed 1,000 lepers with his royal hands, for chastening. The famous Chinese monk Chien Chen (688–763) became a medical missionary to Japan, and while in Nara, he became medical consultant to the Empress Komyo, whose own tragic life led her to take a major interest in the care of patients with leprosy. Chien Chen spent 10 years in Japan and wrote many medical books. He is worshiped as *Kanjin*, the ancestor of medicine.[6] In 740, the Empress Komyo herself provided for the nursing of leprosy patients at the time of the blossoming of Buddhism in Japan, by increasing the hospitals for lepers, which were founded by Prince Shotokautaifa (born 621). It was at this time that the Chinese medical book, *Byogenkoronsenkin-ho*, was carried to Japan, in which leprosy with its characteristic signs was described, which was thought to be due to unhealthy air and an insect that penetrated human flesh. That lepers may go blind was not mentioned. In 833, in Reisikai, a commentary on the law mentioned that leprosy was transmitted to men who were in the vicinity of the afflicted. This insight was apparently lost when the Buddhist priests taught that leprosy was a punishment for sins committed in a previous life. The lepers then suffered pitifully as beggars near the temples.[1]

Leprosy in Medieval and Renaissance Europe

Because of the increase in the number of cases and the horror with which leprosy was regarded during the Middle Ages, it was not a diagnosis to be taken lightly. Nonetheless, it was not only physicians but also laymen who made the diagnosis. In general, diagnosis was conservative, tending to recognize only the most severely affected individuals.

As early as 757, Frankish law permitted divorce because of leprosy. In 1179, the Lateran Council decreed that lepers could not share church, cemetery, or even social life with the healthy. By 1220, it was a civil crime for a leper to live with a nonafflicted individual. The afflicted were officially cut off from the rest of Medieval society. In some parts of Europe they were considered

legally dead and the leper's heirs could inherit his property while he yet lived.[7]

Because leprosy had spread during the Crusades, the Order of Sacred Lazarus was founded in 1048 in Palestine, under Pope Damasius II. The head of the order was frequently afflicted with leprosy himself. By the 13th century, many branches had been established throughout the whole of Europe. Their monasteries were asylums for lepers, where they could remain until they died. Some 19,000 leprosaria were present in Europe by this time—a testimony to the rampant spread of leprosy during the Middle Ages.[1]

Theodoric of Cervia, who was both a bishop and a surgeon (1205–1298), drawing on the earlier medical writings of the Arabic physician Avicenna, described two types of leprosy: one that was self-limited and probably corresponds to tuberculoid leprosy; the other, to lepromatous leprosy. His description of the latter is unmistakable:

> the face becomes puffy, the hairs of the eyebrows and eyelids thin out,... nodules are felt in the skin,... the voice wavers, tending to lower,... patients are pricked in the ankle bone and are unaware, they feel little, similarly on the leg.[5(p301)]

Whereas early in the Medieval period leprosy was less precisely recognized and was equated with heresy, as the diagnosis became more widely and reliably recognized, the social stigmata changed to that reflecting worldliness of the part of the victim: in particular, pride, avarice, gluttony, sexual promiscuity, and neglect of spiritual matters. This change in attitude is reflected in the literature of the period, for example, Dante's *Inferno* and Hartmann von Aue's famous middle-high–German poem "*Der Arme Heinrich*" (The Lamentable Henry).[7]

With time, there was some easing of the social situation for the patient during the Middle Ages. John of Gaddesden in the 14th century counseled that no man be judged a "leper" until his face had been destroyed by the disease. This advice was generally followed, since the diagnosis brought severe legal and religious sanctions. Indeed, seen as the outward figure of an unclean soul, leprosy evoked a special church ceremony in which the "leper" was enjoined to be "dead unto the world, but alive unto Christ."[8(p347)] Later, the Church decreed that leprosy was not grounds for divorce or dissolution of marriage, and the remarriage could not take place until the death of the infected person.[8]

However, within another century leprosy was clearly declining in England, while the population was greatly increasing. Only half of the available hospital spaces were still being used and many of the leprosaria began to be converted to other uses. Indeed, by the time of the Black Death (1347–1350), which killed one third of the population of Europe, many of the leprosaria were empty on the continent as well. In Scandinavia, where the population density was much less, leprosy persisted longer.[8]

Any doubts that the disease in the Middle Ages was leprosy have been dispelled by the paleopathologic studies of Møller-Christensen: he discovered, in Naestved, Denmark, the burial ground of a "lazar" hospital that existed between the years 1250 and 1550. He was able to demonstrate classical changes of lepromatous leprosy in many of the skulls and bones of 202 skeletons that were excavated at this Medieval leprosarium.[5] Characteristic was the destruction of the alveolar process of the maxilla, the loss of central incisors and canine teeth, erosion of the hard palate, and loss of the nasal bone.[8] Similar changes have been noted in skeletons from England and from Aachen, Germany.[7]

By the time of Fracastorius (1478–1553) during the Renaissance, leprosy had waned considerably. However, the rise of syphilis following the discovery of the New World led to the belief in the 16th century that leprosy and syphilis ("the French sickness") were the same disease. Using all the pertinent classical texts, original manuscripts, and the medical works of Pliny, Galen, and Avicenna, Fracastorius critically examined the language and descriptions of leprosy. He noted that the disease known as leprosy was described by the Greeks under the term "elephantiasis," and that the term "lepra" corresponded to milder, no-longer-recognizable conditions. He additionally distinguished the cutaneous nodules of leprosy from syphilis, and emphasized the slow progression of leprosy in contrast to syphilis. Whereas syphilis was considered a venereal disease, leprosy was recognized by Fracastorius to be contagious, transmitted by contact with lesions, by fomites, and by the breath of patients.[9]

Leprosy was first introduced in North America in the middle of the 16th century by immigrants from Europe. Later, slaves from Africa imported leprosy to America and Brazil.[10]

Modern Advances in the Study of Leprosy

One of the greatest strides in the knowledge of leprosy came in 1874, when G. Armave Hansen first described the microorganisms present in nodular leprosy. In 1884, he defined the morphologic characteristics of *M leprae* using a methyl violet staining method, describing rodlike organisms, chains of coccoid forms, and the clumping of organisms that is now called *globi*. Paul Gerson Unna later confirmed this peculiar clumping.[11]

As early as 1884, Patrick Manson described a method of diagnosing leprosy. His suggestion was to squeeze the nodule and then pierce it. Exudate obtained was spread on cover slips or slides. It was dried, stained, and then examined microscopically for organisms. But the major breakthrough for microscopical examination was made by Wade in 1913, when he introduced the skin-slit procedure.

The enigmatic granularity of bacilli frequently seen with acid-fast staining was finally explained by Rees and Valentine in 1962, when they demonstrated by electron micrographs that the irregular acid-fast staining corresponded with degenerative changes in *M leprae*.[11]

The first major therapeutic breakthrough in leprosy came in the 1940s, when sulfones were shown to be

effective against the leprosy bacillus. In 1941, Dr. Guy Faget of Carville, Louisiana, began to use promin, and by 1943 began to report its beneficial effects.[12]

The first successful cultivation of *M leprae* occurred in 1960, when Dr. Charles Shepard of the Centers for Disease Control in Atlanta, Georgia, reported its propagation in the footpad of the mouse. Dr. Waldemar Kirchheimer of Carville, and Dr. Eleanor Storrs of the Gulf South Research Institute in New Iberia, Louisiana, demonstrated an animal model of leprosy in the nine-banded armadillo in 1968. These two advances have had a major impact in the basic understanding of leprosy and have led to a wide range of scientific studies on the nature of and the treatment of the disease.[10]

Leprosy in the U.S. Military

The importance of leprosy as a military problem is limited by certain of its epidemiological characteristics. The most pertinent of these are (*a*) geographical distribution, (*b*) low prevalence rates even in areas in which the disease is considered to be highly endemic, and (*c*) relatively low attack rates in adult life.[2]

For practical purposes, leprosy may be considered a disease of the tropics and subtropics. Every country with high prevalence rates is situated within the tropics, and such tropical countries are inhabited mainly by backward people living in overcrowded huts under conditions favorable to the spread of the disease.

Every country with a very high leprosy rate (ie, 3 or more cases per 1,000 population) is situated in the tropics. In practically all, the climate is hot and damp. The tropical belts of Africa and India are considered to have the highest prevalence rates in the world.[13]

In contrast, prevalence rates are low (< 1 per 1,000 population) in most temperate regions of the world, and are virtually nonexistent in cold climates.[13] The attack rate is very low in adults. Acquisition of the disease normally requires prolonged respiratory contact with a person with untreated lepromatous leprosy. Nonetheless, more than 99% of the exposed population will fail to develop the disease.[14] For the remaining 1% who do, the incubation period averages 2 to 5 years.[10]

Leprosy in the U.S. Army Before World War II

There are no records of leprosy occurring in the U.S. Army before the Spanish-American War. During the War of 1812, troops were engaged in New Orleans in the vicinity of an old endemic focus, but the number of men involved was small and the duration of the conflict short.[2]

The earliest records of leprosy in the armed services of the United States relate to cases among soldiers who served in the Spanish-American War, the Boxer Rebellion, or the Philippine Insurrection. Actually, the cases did not occur during the hostilities; they were reported at intervals over several subsequent decades, and the onset dates are not known with exactness. One or perhaps two of the cases may have originated as early as 1901. From 1921 to 1940, 32 veterans were admitted to the U.S. Marine Hospital (also called the National Leprosarium) at Carville, Louisiana. Of these, 28 had served in the army, three in the navy, and one in the marines. Thirty patients had had military service outside the United States in places known to be focuses of leprosy; 25 of the 30 had served in the Philippines. There is no record of foreign service for two of the patients; one was born in Louisiana and the other in Texas. Five were born outside the continental United States; 19 were born in parts of the United States where the disease rarely occurs. For 18 of the latter, the periods of service in endemic areas ranged from 9 months to 32 years. A large portion of the Spanish-American War veterans who had been admitted to the National Leprosarium were born in nonendemic areas; the average age on admission of the entire group of Spanish-American War veterans was 52. The dates at which the first signs of the disease are stated to have appeared ranged from 1901 to 1938, but, of 27 patients for whom dates are given, all except 4 are stated to have observed their first symptoms after 1910. A number of veterans who developed the disease had remained in the Philippines in military or civilian capacity for some years following termination of the Philippine Insurrection.[2]

From 1921 to 1940, 51 World War I veterans were admitted to the National Leprosarium. Of this population, 41 had served in the army, one in the Students Training Corps, eight in the navy, and one in the marines. Records show that 33 had no service outside the continental United States, 12 had served in France, two in Mexico, and one each in Hawaii, Panama, the Philippines, and Puerto Rico. Of the group of 51, 18 had been born outside the continental United States, and, of the remaining 33, 15 had been born in Louisiana, 10 in Texas, 5 in Florida, 2 in Mississippi, and 1 in Georgia. None had been born in the northern States. Age on admission to the National Leprosarium averaged 33.2 years (range: 22 to 43 y). In 35 patients (68.6%), the first signs of the disease were noticed during the years 1917 through 1923.[2]

Preventive Measures During World War II

Because [*a*] knowledge was lacking about the mode of spread of the disease and [*b*] there were no effective vaccines or chemical prophylactics, there was not much that the U.S. Army's Preventive Medicine Service, Office of The Surgeon General, could do to protect troops and other military personnel against leprosy. Protection depended almost entirely on recognition of the disease when it occurred and avoidance of contact. At the same time, measures were invoked to counteract the fears, the military and public alarm, and the dangers of irrational behavior (eg, violence, hostility) that were aroused by age-old superstitions about the disease. The Preventive Medicine Service recognized that leprosy, because of its long latency and low incidence of adult infection, could not be a disease of military significance insofar as loss of manpower during World War II was concerned. It also recognized that the area of exposure was vastly extended

and that the number of possible contacts was increased when thousands of U.S. soldiers were deployed among populations where incidence of leprosy was high, particularly in the Pacific regions. The late consequences of acquisition of leprosy during the war by soldiers exposed in the course of their service were also matters of grave concern. A balanced program was adopted that was designed to stimulate awareness of the disease and at the same time to support reasonable precautionary measures.[2]

The prevention of contact of military personnel with leprous persons within the service had been a longstanding practice, as specified by army regulations. Leprosy was a fixed basis for rejection of men coming up for induction through enlistment or draft. Despite provisions for rejection on account of leprosy, the records, examined later, showed that 15 men infected with leprosy before 1941 were inducted into the army during World War II. Of these, five were men who had been discharged from the National Leprosarium as "arrested cases." The other 10 men were from various parts of the United States and Hawaii and, at various periods after induction, were discovered to have leprosy. The other 10 men were from various parts of the United States and Hawaii and, at various periods after induction, were discovered to have leprosy. No secondary cases among military personnel are known to have arisen from these sources.[2]

Significant advances were made in the therapy of leprosy during World War II. For many years, the standard treatment had been administration of chaulmoogra oil or its esters, and, although there was controversy as to the results, there was nothing better at hand. In 1940, sulfanilamide was given to a group of patients at the National Leprosarium. However, "although secondary infections were cleared up, little or no improvement was noted in leprous lesions."[2(p34)]

Promin, one of the sulfone drugs (which differ from the sulfonamides in having two phenyl groups instead of one, and which have in common the diaminodiphenylsulfone radical), was released in soluble form for clinical study in 1938. In March 1941, the first group of leprosy patients at the National Leprosarium was placed on promin.[2]

> At first [the drug] was given orally, and toxic symptoms were so severe that it had to be discontinued. Shortly afterward, a preparation for intravenous use was obtained and found to be well tolerated. Clinical improvement observed was slow but definite; as a rule, it did not become manifest until after 6 months of treatment. Lesions of the mucous membranes of the upper respiratory tract responded well, resulting in restoration of the voice and disappearance of nasal obstruction. Emergency tracheotomies were much less frequently required. Nodules in the skin slowly flattened. Areas of infiltration gradually subsided. Leprous ulcers of the extremities gradually healed. Occasionally, regrowth of hair occurred in the eyebrows, beard, and on the arms and legs. There was little evidence of improvement in eye lesions. Skin and nasal smears remained positive in nearly all patients even after a year of treatment, but there was definite evidence of reduction after 2 years of treatment. Slow and gradual disappearance of bacilli was confirmed. Promin appeared to act by eliminating bacillary infection from the blood vessels and bloodstream, thereby preventing formation of new lesions and permitting natural resolution of lesions to take place.[2(p34)]

Promin was in part replaced in 1943 by disodium formaldehyde sulfoxylate diaminodiphenylsulfone, first prepared under the name of Diasone. It was given orally in doses as large as about 1 g daily. Other sulfones soon came into use, but the results with all of them were more or less equivalent to those obtained with Diasone. It is considered by many that beneficial effects of the sulfones on leprosy are attributable to diaminodiphenylsulfone (DADS).[2]

Records have been found of 69 cases of leprosy in individuals who served in the armed forces during World War II. In 15 of the 60 leprosy patients from the army, there is evidence that the disease had been present before enlistment or induction, and 5 of the 15 had been treated previously at the National Leprosarium. Of the other 45 patients, 7 had definite histories of exposure to leprosy in the family. The records of the remaining 38 patients were carefully examined in the search for the probable loci of exposure. All but six had been born in the areas in which the disease is endemic [*eg, the Gulf coasts of Louisiana and Texas—JWS*]. While this does not preclude the possibility of exposure during military service, it would seem more probable that the infection occurred at an earlier date. This is supported by the fact that the average age of these patients at time of stated onset was 27.2 years and also by the fact that there was no significant difference in average age at time of onset between those who had served in theaters in which the disease was endemic and those who had not.[2]

Leprosy During the Vietnam Conflict

The only statistics on leprosy reported out of the Vietnam conflict dealt with indigenous Vietnamese patients seen at the 95th Evacuation Hospital Da Nang, I Corps, from July to October 1970. Fourteen cases, constituting 13% of the total (114) population presenting with skin diseases, were seen.[15(p41)]

EPIDEMIOLOGY

The World Health Organization (WHO) currently estimates the prevalence of leprosy at 10 to 12 million cases, based on some 3.7 million registered cases, with 576,361 new cases detected in 1990 (Figure 14-1).[13,16]

The portal of entry for leprosy bacillus most probably is the respiratory tract, although there is evidence for transmission of leprosy through intact skin and via penetrating wounds such as thorns and

Fig 14-1 is not shown because the copyright permission granted to the Borden Institute, TMM, does not allow the Borden Institute to grant permission to other users and/or does not include usage in electronic media. The current user must apply to the publisher named in the figure legend for permission to use this illustration in any type of publication media.

Fig. 14-1. The world distribution of registered leprosy cases as of 1990. Data source: Noordeen SK. Leprosy control through multidrug therapy (MDT). *Bull WHO*. 1991;69:264.

arthropod bites.[14] It is widely accepted that the nose is the major portal of exit for bacilli. Multibacillary patients can shed several millions of bacilli per day in their nasal secretions.[16] Patients with untreated lepromatous leprosy have great numbers of bacilli in their nasal secretions. However, patients with borderline and tuberculoid disease have few to none. Chemotherapy rapidly renders the nasal discharge bacteriologically negative. Longitudinal studies have repeatedly confirmed that multibacillary patients constitute the major source of infection.

The decline in leprosy documented in some countries at a time of improvement in living conditions, but before the advent of modern control measures, suggests that mitigation of overcrowding and poverty, as well as improvements in nutrition and hygiene, have beneficial effects in preventing the disease.[16]

While humans are considered to be the major host for the leprosy bacillus, natural infections of wild armadillos occur in Texas and Louisiana, and natural infections of chimpanzees and mangabey monkeys occur in the wild.[16] Anecdotal reports suggest that transmission of *M leprae* between armadillos and humans is possible.

Children, particularly infants and young children, seem to be much more susceptible to leprosy than adults in a given population. Where children are at risk because of leprosy in the family, up to 60% will develop disease after a 2- to 7-year incubation period. Thus, peak ages of incidence are ages 5 through 9 years.[17] In contrast, the incidence of conjugal leprosy in spouses is only about 5%.[5] Transplacental transmission has rarely been documented.[17] However, one series[18] of 91 children less than the age of 1 year in whom leprosy was diagnosed has been reported. In children, paucibacillary forms of leprosy tend to predominate, with most children expressing indeterminate and tuberculoid lesions.[17] However, in a recent series of 132 children from a nonendemic area of northern India, 59% had

borderline tuberculoid (BT) disease and 20.4% had borderline lepromatous (BL) disease. Only 3.8% had indeterminate leprosy.[19] Also noteworthy is the high frequency of nerve involvement in children (seen in two thirds of all cases) and the low frequency of reactional states.[19] Nonetheless, most people effectively resist infection even in highly endemic areas. It is now believed that only 0.5% of those infected with the leprosy bacillus actually develop an overt clinical case.[14]

The clinical profile of leprosy has changed considerably since the mid-1970s. Advanced lepromatous leprosy with leonine facies, ulcerating nodular lesions, and progressive ulcerative erythema nodosum leprosum leading to amyloidosis, nephrotic syndrome, and death are less frequently observed. Such improvements are attributable to efficient leprosy control programs and improvements in chemotherapy.[16]

Pregnant women with incubating leprosy may develop overt signs of disease; most women worsen during pregnancy. Reversal reactions occur during puerperium, downgrading reactions during the third trimester. Erythema nodosum leprosum reactions are most likely in the third trimester and following parturition. Infants born of lepromatous mothers tend to be small for their gestational age.[5]

MICROBIOLOGY

As seen in slit-skin smears, *M leprae* is a straight or slightly curved, rod-shaped organism with parallel sides and rounded ends. It measures 1 to 8 µm in length and 0.3 µm in diameter. *M leprae* is Gram-positive with the additional property of resisting decoloration of carbol-fuchsin with acid alcohol. It is primarily an intracellular organism commonly seen in clumps (*globi*), which may contain hundreds of bacilli. In clumps, they occur in parallel array and resemble bundles of cigars.

M leprae grows best at 27°C to 30°C (ie, in the cooler parts of the body). It divides every 12 to 15 days. The organism may be a natural soil saprophyte.

Natural Reservoirs and Laboratory Transmission

Investigations into the basic biology, metabolism, and chemical structure of *M leprae* have been hindered by the inability to date to culture the organism in vitro. Additionally, it seems to multiply and produce disease in only a very limited number of animal species. The nine-banded armadillo is currently the only source of the large amounts of leprosy bacillus needed for research purposes and vaccine production. Inoculation into the footpads of immunologically normal mice remains the basic tool for assessing drug activity and resistance of *M leprae*. The use of immunodeficient rodents (ie, thymectomized, irradiated, bone marrow–reconstituted mice, nude mice, and neonatally thymec-tomized rats) is the most sensitive method available for monitoring the presence of viable *M leprae* in patients undergoing chemotherapy.[16]

Experimental transmission of infection to three different species of monkey has been achieved within the last decade: lepromatous leprosy (LL) in mangabey monkeys, borderline lepromatous leprosy (BL) in African green monkeys, and borderline lepromatous–lepromatous leprosy (BL-LL) in rhesus monkeys.[16]

The Cell Wall

The cell walls of all mycobacteria exhibit a similar complex structure of lipid-rich macromolecular structures. However, *M leprae* appears to differ from other mycobacteria in the composition of the peptide units and in the multiplicity of peptidoglycan layers that constitute the complete cell wall structure (Figure 14-2). The most notable of the cell wall–associated glycolipid molecules of *M leprae* is phenolic glycolipid I (PGL-1), which is species-specific and immunogenic during infection. Immunochemical and electron micrographic studies indicate that PGL-1 is associated with the outer surface of *M leprae* and may represent the "capsule" of the organism. This could function as a virulence factor, providing an important interface between parasite and host, critical for maintenance of the parasitic relationship. PGL-1 can accumulate in armadillo tissues in quantities equal to one half the total weight of the leprosy bacilli present. The "foam" seen in heavily infected macrophages—a characteristic of the lepromatous granuloma—is thought to contain PGL-1.[14]

Molecular Biology and Genetics

The advent of monoclonal antibody techniques and T-cell cloning methods has permitted the iden-

Fig 14-2 is not shown because the copyright permission granted to the Borden Institute, TMM, does not allow the Borden Institute to grant permission to other users and/or does not include usage in electronic media. The current user must apply to the publisher named in the figure legend for permission to use this illustration in any type of publication media.

Fig. 14-2. *Mycobacterium leprae* has a complex cell wall composed of many layers. The outer layer contains the phenolic glycolipid PGL-1, which may be an important virulence factor. Adapted with permission from Gaylord H, Brennan PJ. Leprosy and the leprosy bacillus: Recent developments in characterization of antigens and immunology of the disease. *Annu Rev Microbiol.* 1987;41:645–675.

tification of a number of epitopes (as opposed to entire protein molecules) unique to *Mleprae*. The entire genome of *M leprae* has been cloned and expressed in *E coli*; this development has opened a wide avenue for future research, despite the absence of in vitro culture techniques.[16]

IMMUNOLOGY

Humoral Immunity

Because of the intracellular, sequestered location of *M leprae*, it is doubtful that humoral immunity plays a significant role in resistance to the organism. However, humoral immunity is the source of the antigen–antibody complexes in the pathogenesis of erythema nodosum leprosum reactions. Lepromatous leprosy (LL) is generally associated with hypergammaglobulinemia and a high circu-

lating B lymphocyte count. Patients with borderline leprosy (BB) tend to have intermediate levels, and patients with tuberculoid leprosy (TT) have normal levels of B lymphocytes. There tends to be an inverse correlation between a patient's anti–*M leprae* antibody titer and the potency of the patient's cell-mediated immune response to the bacillus.[14]

PGL-1 was the first antigen specific to *M leprae* to be identified and to have its antigenic moiety chemically synthesized. Antibodies to PGL-1, primarily of the immunoglobulin (Ig) M subclass, have been detected in the sera of most multibacillary patients with leprosy, in titers proportional to the bacillary load. In some limited studies, high antibody titers have also been reported in some household contacts of multibacillary patients, as well as in other habitants of endemic areas, confirming that infection is more frequent than overt disease. However, false-negative results in patients with tuberculoid leprosy (TT) and their contacts limits the use of antibody titers for epidemiological purposes or for detection of subclinical infection.[16]

Cell-Mediated Immunity

Experiments involving inoculations of *M leprae* into athymic (nu/nu) mice and rats have shown the importance of cell-mediated immunity in host resistance to leprosy.[14] The maximum number of T lymphocytes tends to be present in tuberculoid lesions, with a gradual decline across the spectrum such that very few are present in disseminated multibacillary lepromatous leprosy.[20]

At the lymphocyte level, the presence of T helper cells specific for antigens of the leprosy bacillus is a key characteristic of the tuberculoid end of the clinical spectrum of leprosy. T helper cells have been found to be as high as 95% of the lymphocytes in tuberculoid granulomas, whereas in lepromatous lesions T cytotoxic/suppressor cells can constitute up to 85% of the population.[20] More importantly, in tuberculoid lesions the cells are arranged in a distinct architecture within the lesion: T4 cells in the centers of the epithelioid granulomas and T8 suppressor cells in the margins.[14] T4 cell counts are often depressed and T8 cell counts increased in the peripheral bloodstream of many patients with lepromatous leprosy in proportion to their bacillary load.[20] These abnormal T cell counts slowly normalize with adequate chemotherapy.[20]

Additionally, in lepromatous disease, the macrophage fails to kill or inhibit *M leprae* and is unable to produce interleukin-1 (IL-1), the cytokine that can amplify the production of IL-2 by T cells. Macro-phages, activated by lymphokines (especially gamma interferon [IFN-g], which is released from sensitized helper T cells responding specifically to antigen), may play a major role in resistance to a wide variety of obligate and facultative intracellular pathogens. In an experimental model of leprosy of the lepromatous lepromatous (LL) type, it has recently been demonstrated that *M leprae*–engorged macrophages from the footpad lesions of infected nude mice (nu/nu) are refractory to IFN-g in vitro. Of interest, lipoarabinomannan (LAM), a carbohydrate-rich component of the *M leprae* cell wall, not only blocks the proliferation of T cells, but also induces a refractory response to IFN-g in human monocyte-derived macrophages. Thus, newly arriving macrophages may rapidly encounter local bacterial-wall products that effectively restrict their normal responsiveness and function.[14] Hence, they may then fail to produce IL-1, leading to nonreactive, nonproliferative T cells in that microenvironment.

The Lepromin Test

The lepromin test is an indicator of the ability of the host to mount a cell-mediated immune response to *M leprae.* Lepromin is a heat-killed suspension of *M leprae* originally obtained from homogenized human tissue sources, but now prepared from armadillo tissue. WHO's Expert Committee on Leprosy has recommended standardizing the concentration at 40 million bacilli per milliliter.[14] The test itself is of no diagnostic value, but does establish the immune status of the individual and is thus of prognostic value. A positive reaction is typically biphasic:

- The early (24–48 h) Fernandez reaction is a delayed hypersensitivity reaction (probably to soluble protein antigens) and occurs in patients with tuberculoid leprosy, their contacts, and healthy individuals who are sensitized either to *M leprae* or to cross-reacting antigens from other mycobacteria.
- The late Mitsuda reaction, measured at 21 days, reflects the induction of acquired cell-mediated immunity, which is manifested by formation of an organized epithelioid cell granuloma. WHO has instituted the following system for grading the Mitsuda reaction[20]:
  - 0 No reaction (induration)
  - ± Induration or papules less than 3 mm

1+ Induration or papules 4 to 6 mm
2+ Papule 7 to 10 mm
3+ Nodule larger than 10 mm, or of any size that ulcerates

Positive reactions are seen in the vast majority of contacts and unexposed individuals, as well as in patients with tuberculoid leprosy. Weakly positive reactions aid classification of borderline disease. Negative reactions are seen in lepromatous leprosy, despite years of chemotherapy.

LABORATORY DIAGNOSIS

The Slit-Skin Examination Technique

Bacteriological examination is very important and highly relevant to leprosy control. The slit-skin technique (in simple terms, a slit-scrape-smear method) is the WHO-preferred method for the detection of bacteria in patients suspected of harboring the leprosy bacillus[11]:

- Thoroughly clean the selected portion of skin to remove saprophytic acid-fast bacilli.
- Pinch the skin to remove blood and decrease hemorrhage.
- Using a sterile surgical blade, make a cut 5-mm long by 2-mm deep.
- Wipe away any oozing blood.
- Holding the blade at right angles to the slit, scrape the bottom and sides of the slit with the point of the blade to obtain sufficient material for a smear.
- Transfer the material to a clean, labeled, glass slide.
- Use pressure hemostasis to stop bleeding at the slit site.

It is essential that the Centers for Disease Control and Prevention's guidelines[21] for preventing the transmission of AIDS and hepatitis B infection be followed during the process of taking skin smears.

Site Selection

In lepromatous leprosy, the skin and the mucous membranes of the nose and oral cavity are diffusely infiltrated with bacteria—even in areas that appear normal. In tuberculoid leprosy, organisms are sparse. In borderline leprosy, only the borderline lepromatous (BL) group may show bacilli in uninvolved sites. Thus, in lepromatous leprosy, it is a question of selecting a site with the highest density of bacteria, whereas in tuberculoid and borderline groups, one has to select from lesions only. The ear has traditionally been regarded as the site of heaviest involvement. The chin, buttocks, and fingers are also sites of high bacillary counts. Recently, it has been noted that in long-treated cases, the bacilli are probably cleared from the fingers last.[11]

In general, smears should be taken from a minimum of three sites, including one ear lobe and two representative active skin lesions. In cases of paucibacillary patients with one lesion, two smears should be taken from the active border, diametrically opposite each other.[16] Sites previously shown to be positive in specific patients are recommended as sites for follow-up examination.

Acid-Fast Preparations

The Ziehl-Neelsen acid-fast staining of slit-skin smears is the global standard, being inexpensive and requiring minimal facilities. Smears should be dried for 15 to 30 minutes and fixed. Fixation can be done by passing slides carefully through a flame. However, it is preferable to fix the smears in 40% formaldehyde for 15 minutes. Slides are then stained by the Ziehl-Neelsen method, a complex, regressive, staining method comprising three essential steps[22]:

1. Over-staining with basic fuchsin. This is achieved by using carbol-fuchsin containing phenol and applying heat, or keeping the staining solution on the slide for a period of time. Under field conditions the cold staining method is easier. The basic fuchsin is left on the slide for 30 minutes.
2. Decoloration (this is a regressive step) with either acidified alcohol or acid in water. All material except mycobacteria (in this case, *M leprae* or *M tuberculosis*) lose the red fuchsin stain. At this moment, leprosy bacilli in the preparation are stained red on a colorless background.
3. Counter-staining of the background with methylene blue.

Bacterial Index

In the past in developing countries, the bacterial examination had largely been neglected. This practice was somewhat acceptable as long as therapy was based on one and only one drug, which was administered to patients no matter what form of the disease they had. However, now the differentiation of paucibacillary leprosy from multibacillary leprosy takes on added importance, as the two forms use different therapeutic regimens. The Ridley Logarithmic Scale,[23] proposed in 1958 as a bacterial index, has gained wide acceptance; WHO has recommended its uniform adoption worldwide to facilitate comparison of results.[16] Ridley's Logarithmic Scale is as follows:

6+ Many clumps of bacilli in an average field (> 1,000)
5+ 100–1,000 bacilli in an average field
4+ 10–100 bacilli in an average field
3+ 1–10 bacilli in an average field
2+ 1–10 bacilli in 10 fields
1+ 1–10 bacilli in 100 fields
0 No bacilli seen

Before a case is deemed negative, 200 fields are generally scanned. Otherwise, the bacterial index of the patient is averaged from all the bacterial indices of the individual sites.

The line between paucibacillary and multibacillary cases is a bacterial index of 2 or more at any site. Because of drug resistance and the need for multidrug therapy, the microscopical examination of smears for acid-fast bacilli is quite essential to detect relapse. Reading and interpretation of the bacterial index can be schematized as follows[22]:

- In patients with new, untreated leprosy:
  - 0 No leprosy or paucibacillary leprosy
  - 1 Bacteriologically proven paucibacillary leprosy
  - ≥2 Multibacillary leprosy
- In patients with old, previously treated leprosy:
  - 0 No leprosy, or treated paucibacillary or multibacillary leprosy
  - 1 Treated multibacillary leprosy
  - ≥2 Multibacillary leprosy, keeping in mind that adequate treatment diminishes the bacterial index by approximately 1 unit per year

Thus, these results should be interpreted taking into consideration the kind and duration of previous treatment. Notably, a significant increase of the bacterial index is the result of either irregular drug intake or development of drug resistance.

There is a widespread impression that multidrug therapy will hasten the attainment of smear negativity, but this is not substantiated by the available evidence. The rate of clearance of bacilli under multidrug therapy is approximately 0.6 to 1 Ridley Logarithmic Scale units per year. It must be appreciated that the bacterial index is a late marker for the antibacterial action of drugs in leprosy, even though it is of prime importance for the diagnosis of relapsed cases. Clinical improvement is accelerated by multidrug therapy and precedes the fall in the bacterial index.[16]

Bacilli in smears are seen only when the bacillary load is more than 10^4 organisms per gram of tissue. Negative results from a slit-skin examination do not exclude leprosy: organisms can be seen in biopsied specimens of skin, peripheral nerves, lymph nodes, and testes despite cutaneous negativity.[11]

The greatest importance of positive slit-skin examinations is probably in the diagnosis of indeterminate leprosy.

For treatment purposes, WHO has recently redefined multibacillary and paucibacillary disease. Paucibacillary disease is smear-negative, and multibacillary smear-positive.[16]

Both for patients currently under treatment and for patients previously treated, WHO has laid down certain guidelines for assessment. Both past and present bacterial indices should be considered. Patients are classified as paucibacillary or multibacillary on the basis of the highest bacterial index at any time during treatment.

The bacterial index is a direct measure of the bacillary load of an individual, and therefore of the seriousness and infectiousness of the patient's condition. Clearly, patients with a high bacterial index (ie, those with lepromatous leprosy) are more infectious. Prolonged skin-to-skin contact with such patients is a known mode of transmission of leprosy. Bacilli may also be continuously shed from nasal discharge into the environment. Thus, a high bacterial index from the nose may have great epidemiological significance. Maximum load is harbored in patients having a bacterial index of more than 3; a priority treatment for these patients is therefore logical. Bacterial load decides the severity and infectivity of the case.

A patient should be regarded noninfective if he or she has a bacterial index of 0, determined from multiple slit-skin smears repeated over 3 consecutive months.[11]

Morphologic Index

Traditionally, the morphologic index was thought to give an indication of the proportion of viable bacilli in the patient. This viability was based previously on the percentage of bacteria with solid staining, as opposed to fragmented or granular staining. More sophisticated techniques such as electron microscopy, mouse-footpad inoculation, thymidine uptake studies, and so forth, have shown poor correlation between the morphologic index and true viability.[11] Additionally, there are problems with reproducibility and standardization, especially under field conditions. Therefore, WHO does not recommend its use in routine control programs.[16]

Cutaneous Nerve Biopsy

A cutaneous nerve biopsy is frequently required to establish the diagnosis of primary neuritic leprosy (discussed later in this chapter). Patients with this form of leprosy have no cutaneous lesions other than localized anesthesia. Because standard skin biopsies and smears for acid-fast bacilli are usually nondiagnostic, cutaneous nerve biopsy may be the only method by which the condition can be diagnosed with certainty. The procedure for performing cutaneous nerve biopsy is as follows[24]:

1. Find a palpable nerve in the area of anesthesia and mark the skin overlying it with gentian violet.
2. Give local anesthesia.
3. Make a transverse incision 1 cm in length over the nerve.
4. Tease through the subcutaneous tissue gently with an artery forceps until the nerve is identified.
5. Remove a 1-cm piece of nerve with a scalpel.
6. Suture skin closed.
7. Process the specimen for routine histopathology and for acid-fast bacilli.

Serologic Assays

Cases of subclinical infection can now be detected by serologic means including fluorescent leprosy absorption, radioimmunoassay for antibodies to cell-wall antigen, and enzyme-linked immunosorbent assay (ELISA) to detect antibodies against the phenolic glycolipid derived from the *M leprae* cell wall.[10] However, because only 0.5% of those infected with the leprosy bacillus are believed to actually develop overt clinical leprosy, it is difficult to interpret the meaning of a positive test, other than for epidemiological investigations.[14]

CLINICAL AND HISTOLOGICAL DIAGNOSTIC CRITERIA

Clinically, leprosy demonstrates a wide spectrum of dermatologic lesions.[25,26] Untreated patients may present with any combination of the following:

- a single, nondescript, hypopigmented macule;
- single or multiple, asymmetric, dry, scaly, or inflammatory plaques;
- symmetrical, widely disseminated, erythematous papules and nodules associated with coarse thickening and nodularity of the face (leonine facies);
- lagophthalmos (Figure 14-3);
- blindness;
- severe peripheral neurological disease;
- deformities of the nose and extremities; or
- diffuse infiltration and edema of the skin.

Secondary cutaneous infections, osteomyelitis, neurotropic ulcerations, and significant renal disease (amyloidosis or glomerulonephritis) may occur in severely affected and untreated patients. Additionally, psychiatric abnormalities are not uncommon among patients with leprosy. A study of 81 patients conducted over a 4.5-year period at the Hansen's Disease Center in Carville, Louisiana, showed that more than 80% of the patients had a psychiatric disorder: 37 (46%) had a major affective disorder; 9 (11%) had an organic mental disorder; 9 (11%) had schizophrenia; and 9 (11%) had substance abuse.[27] The large number of patients with affective disorder and substance abuse may well be due to the emotional effect of the diagnosis on patients and their families in our society.

Histologically, established leprosy demonstrates a continuous spectrum of disease from a localized, self-healing, granulomatous disease with very few organisms to a widespread, progressive, anergic disease with massive numbers of bacilli.[28] *M leprae* tend to invade neuronal structures in the cooler areas of the body. Initially, only minor nerve infiltration may be demonstrated histologically. However, great variation is present from patient to patient.

OK to print

To classify patients within this tremendous clinical and histological spectrum, several classification schemes have been proposed. The most popular, and the one endorsed by WHO, is the Ridley and Jopling Classification, with minor modifications (Table 14-1 and Figure 14-4). Histological classifications, by contrast, are much more expensive (and are thus impractical for use in third-world countries and in field situations) and they do not help further categorize patients except for those in the reactional states (which are discussed later in this chapter).[28] Exhibits 14-1 through 14-7 and Figures 14-5 through 14-12 are designed to aid in the diagnosis of leprosy in its various manifestations.

The polar forms—lepromatous leprosy (LLp) and tuberculoid leprosy (TTp)—tend to be stable clinically, whereas the borderline forms—borderline lepromatous (BL), borderline leprosy (BB), and borderline tuberculoid (BT)—tend to be unstable. The

Fig. 14-3. This patient has advanced lepromatous leprosy with significant cutaneous and ocular disease. Note the severe lagophthalmos, which has led to an exposure keratitis, and the severe deformity of the fingers, which is a consequence of chronic trauma and secondary infection following anesthetic changes in the distal extremities.

TABLE 14-1

MODIFIED RIDLEY-JOPLING CLASSIFICATION FOR LEPROSY

	Characteristics of Lesions				
Stage of Disease	**Number**	**Size**	**Surface**	**Sensation***	**Hair Growth**
Polar lepromatous (LLp)	Very many	Small	Shiny	Not affected	Not affected
Subpolar lepromatous (LLs)	Very many	Small	Shiny	Not affected	Not affected
Borderline lepromatous (BL)	Many	Variable	Slightly shiny	Slightly diminished	Slightly diminished
Borderline borderline (BB)	Several	Variable	Dry	Slightly to moderately diminished	Moderately diminished
Borderline tuberculoid (BT)	Few or 1	Variable	Dry	Moderately to markedly diminished	Moderately diminished
Subpolar tuberculoid (TTs)	Usually 1	Variable	Very dry	Absent	Absent
Polar tuberculoid (TTp)	Usually 1	Variable	Very dry	Absent	Absent

*Does not pertain to lesions on the face
†AFB: Acid-fast bacilli

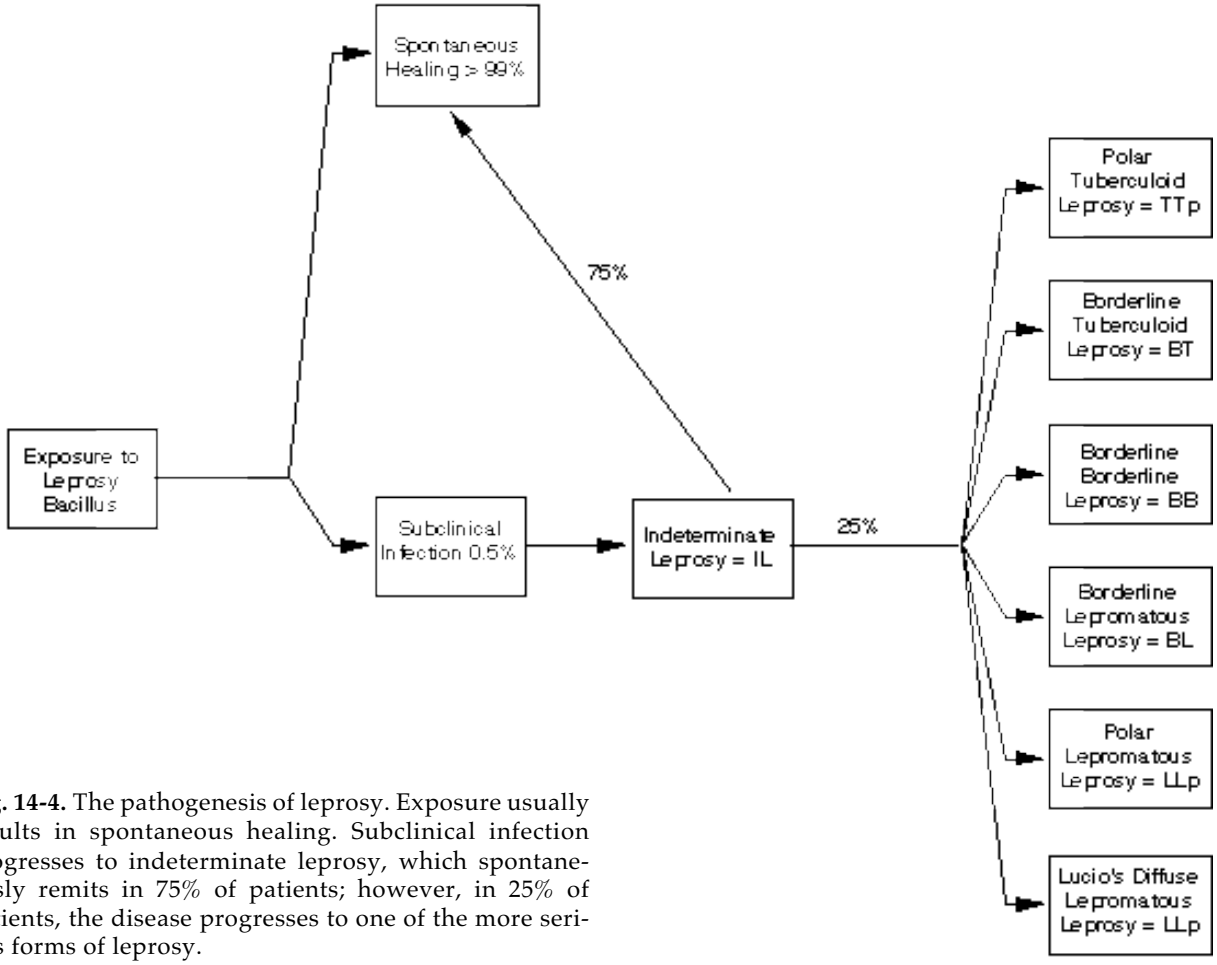

Fig. 14-4. The pathogenesis of leprosy. Exposure usually results in spontaneous healing. Subclinical infection progresses to indeterminate leprosy, which spontaneously remits in 75% of patients; however, in 25% of patients, the disease progresses to one of the more serious forms of leprosy.

Contain AFB†	AFB Found in Nasal Secretions	Bacterial Index (Ridley)	Lepromin Test	Comment
Very many (plus globi)	Very many (plus globi)	5–6	Negative	Polar lepromatous leprosy
Very many (plus globi)	Very many (plus globi)	5–6	Negative	Downgraded to LL from BL due to lack of therapy
Many	Usually nil	4–5	Negative	Unstable immunity
Moderate	Nil	3–4	Negative	Unstable immunity
Nil or scanty	Nil	0–2	Weakly positive (+ or ++)	Unstable immunity
Nil	Nil	0–1	Strongly positive (+++)	Upgraded to TT from BT due to treatment or nutrition
Nil	Nil	0–1	Strongly positive (+++)	Polar tuberculoid leprosy

EXHIBIT 14-1

THE DIAGNOSIS OF LEPROMATOUS LEPROSY

OK to print

OK to print

Fig. 14-5. Lepromatous leprosy. This elderly man has innumerable erythematous infiltrated papules and plaques on his back. Notice the sparing of the spinal and immediate paraspinal areas. These zones are warmer and are consequently less hospitable to the growth and survival of *Mycobacterium leprae*.

Fig. 14-6. Lepromatous leprosy. This teenaged Peruvian girl has a more nodular form of lepromatous leprosy (compared with the patient shown in Fig. 14-5). Note the symmetry of the lesions and the diffuse infiltration of her nose.

Clinical Features

- The number of lesions is characteristically numerous to uncountable. They are bilaterally symmetric, widely distributed, hypopigmented (ie, dark-skinned) or erythematous, and may take any of these forms: macules, plaques, papules, and nodules (Figures 14-5 and 14-6).
- The margins of macules are hazy (ie, they merge imperceptibly into the surrounding skin).
- The lesions are smooth and shiny.
- The ears may be infiltrated (Figure 14-7.)
- The face may become exceedingly infiltrated with nodules, creating the leonine facies.
- The axillae, groin, perineum, and hairy scalp are almost invariably spared of lesions.
- Chronic edema of the lower extremities is common.
- Eyebrows are frequently lost, although body hair and scalp hair are generally retained.
- Lagophthalmos and corneal anesthesia leading to exposure keratitis are common with advanced disease.
- Sweating is often normal.
- Multiple nerve thickenings occur only in the late states of the disease: great auricular nerves in the neck, supraclavicular nerves, ulnar nerves (olecranon fossae), radial and medial nerves at the wrist, lateral popliteal nerves, sural nerves, and posterior tibial nerves.

Exhibit 14-1 (continued)

OK to print

Fig. 14-7. Lepromatous leprosy. This elderly Peruvian man shows characteristic infiltration of the ears and ear lobes. Note the multiple nodules and papules on his face, many of which appear to be subcutaneous.

OK to print

Fig. 14-8. Histology of lepromatous leprosy, low power. Foamy histiocytes loaded with *Mycobacterium leprae* bacilli are found diffusely infiltrating the dermis. Note the typical grenz zone beneath the epidermis and adjacent to the hair follicle.

OK to print

Fig. 14-9. Histology of lepromatous leprosy, oil emersion, Fite stain. Large numbers of acid-fast organisms are seen singly as well as in clusters (globi).

Clinical Features (*continued*)

- Nasal stuffiness, crusting, and discharge are characteristic. Discharge is striking for the large number of acid-fast bacilli.
- There may be systemic infiltration of liver, spleen, bone marrow, kidneys, and testes.

Histological Features

- The numerous, foamy macrophages in the dermis around blood vessels, nerves, and adnexa are characteristic. The entire dermis may not be involved (Figure 14-8).
- A well-preserved grenz zone is typical.
- The nerves are preserved and have an "onion peel" appearance.
- Acid-fast bacilli are numerous and are found in packets (ie, globi) within the macrophages (Figure 14-9). Older lesions show vacuolated cytoplasm within the macrophages due to lipid accumulation (ie, the lepra cells of Virchow).
- Bacterial Index (Ridley) = 5–6

EXHIBIT 14-2

THE DIAGNOSIS OF TUBERCULOID TUBERCULOID LEPROSY

OK to print

OK to print

Fig.14-11. Tuberculoid leprosy, low power. Elongated, noncaseating granulomata coursing along the peripheral nerve twigs are characteristic.

Fig. 14-10. Tuberculoid leprosy. A young Filipino man presented with this single, anesthetic, peripherally infiltrated plaque on his ankle. Note the central clearing and postinflammatory hypopigmentation.

Clinical Features

- One or a few hypopigmented or erythematous macules and plaques may be seen.
- The plaques are well defined, dry, scaly, and indurated (particularly at the periphery), and somewhat saucer shaped. The lesions may show central clearing or postinflammatory hyperpigmentation (Figure 14-10).
- Due to significant nerve involvement, impairment or complete loss of sweating and of sensation are common within the lesions.
- Alopecia may be partial or complete within the lesions.
- Thickening or tenderness or both in the nerves feeding or supplying the patch may be appreciated.

Histological Features

- Compact, often elongated, epithelioid granulomas surrounded by lymphocytes tend to be located just beneath the epidermis, and extend to the middermis or deep dermis (Figure 14-11).
- Infiltration and complete destruction of small cutaneous nerves is a constant feature (nerves may be unidentifiable). Histiocytes may be seen within the small nerves.
- The acid-fast bacilli are difficult to demonstrate by special stains, but can be seen with electron microscopy.
- Bacterial Index (Ridley) = 0–1

EXHIBIT 14-3

THE DIAGNOSIS OF BORDERLINE BORDERLINE LEPROSY

Clinical Features

- The lesions of borderline leprosy show morphology combining features of both tuberculoid and lepromatous leprosy.
- The number of lesions resembling tuberculoid morphology is almost equal to those resembling lepromatous leprosy.
- Lesions are bilateral but asymmetrical.
- Lesions are numerous but countable.
- Nerves may be thickened or tender or both.

Histological Features

- The granuloma is marked by the presence of epithelioid cells, absence of giant cells, and scanty lymphocytes scattered all over the lesion.
- A subepidermal zone relatively free of lesions is formed.
- The structure of the nerves is generally maintained, although they have been infiltrated by epithelioid cells.
- The acid-fast bacilli are easily demonstrable.
- Bacterial Index (Ridley) = 3–4

EXHIBIT 14-4

THE DIAGNOSIS OF BORDERLINE LEPROMATOUS LEPROSY

Clinical Features

- Lesions show morphology of both tuberculoid and lepromatous leprosy. However, the lesions resembling lepromatous morphology are much more numerous than those resembling tuberculoid.
- The lesions are bilateral and tend to be symmetrical.
- The lesions are numerous and may be uncountable.
- Nerves may show thickening or tenderness or both.

Histological Features

- The presence of granulomata consist of histiocytes, lymphocytes, and macrophages containing acid-fast bacilli. The granulomata are diffuse and located in the mid- and lower dermis.
- The structure of the nerves is maintained, although they are infiltrated by histiocytes. Their classic "onion-peel" appearance is the hallmark of the diagnosis.
- Acid-fast bacilli are easily identifiable.
- Bacterial Index (Ridley) = 4–5

EXHIBIT 14-5

THE DIAGNOSIS OF BORDERLINE TUBERCULOID LEPROSY

Clinical Features

Borderline tuberculoid leprosy may appear similar to tuberculoid tuberculoid leprosy, with the following exceptions:

- Satellite lesions are present.
- Lesions number fewer than 10.

Histological Features

- The well-developed granulomata are formed by epithelioid cells and plentiful lymphocytes. Giant cells are either absent or occasional. The granulomata are elongated due to their presence along the nerves.
- Dermal nerves are swollen with infiltrate, but are recognizable in the earlier stages. Later the nerves may be destroyed by the granulomatous reaction. Another common pattern is an intense epithelioid cell granulomatous infiltrate encroaching on the basal epithelium.
- Bacterial Index (Ridley) = 0–2

EXHIBIT 14-6

THE DIAGNOSIS OF INDETERMINATE LEPROSY

Clinical Features

- The number of lesions is usually one or a few.
- The lesions are hypopigmented, irregularly shaped macules in patients with dark skin, and may be erythematous in patients with lighter skin.
- The lesion margins are vague and ill-defined.
- Their surface is smooth and no infiltration is present.
- Sensations are equivocal.
- Nerves may or may not be thickened.

Histological Features

- There is a lymphocytic and histiocytic infiltrate around the adnexa, blood vessels, and nerve twigs of the upper dermis. The diagnosis requires clinical suspicion and is confirmed by the finding of acid-fast bacilli within the nerves.
- Bacterial Index (Ridley) = –/+

EXHIBIT 14-7

THE DIAGNOSIS OF PRIMARY NEURITIC LEPROSY

OK to print

Fig. 14-12. This patient has advanced neuritic leprosy. Note the interosseus muscle wasting in the hand caused by infiltration and destruction of the peripheral motor nerves.

Clinical Features

- There are no skin lesions—either present or past.
- Nerves are thickened or tender or both.
- The involvement of the nerves is asymmetrical.
- Sensations are lost in this order: temperature, touch, pain.
- Tendon reflexes normal or exaggerated.
- The muscles supplied by affected nerves atrophy (Figure 14-12). In the late stages, contractures and deformities may be present.

Histological Features

- A histological diagnosis of indeterminate leprosy is made when the nerve shows lymphocytic infiltration.
- A diagnosis of tuberculoid tuberculoid leprosy is made when the infiltrate contains epithelioid cells (with or without giant cells) and lymphocytes.
- A diagnosis of borderline borderline leprosy is made when some foam cells are present in addition to the above.
- A diagnosis of lepromatous leprosy is made when macrophages are filled with acid-fast bacilli and a round cell infiltrate.
- A diagnosis of lepromatous neuritis is made when a mononuclear infiltrate is present, with fibrosis and hyalinization.

lepromatous leprosy group has been subdivided into polar lepromatous (LLp) and a subpolar lepromatous (LLs) forms. The subpolar lepromatous classification is used to differentiate those patients who were previously in an unstable borderline group and who "downgraded" into lepromatous disease through lack of treatment and waning immunity. The main reason for the subdivision is that the patients in the subpolar lepromatous leprosy group are capable of regaining their lost cell-mediated immunity during an "upgrading" (ie, reversal) reaction. Thus, although their conditions resemble polar lepromatous leprosy clinically, these patients are immunologically unstable, and, with chemotherapy, may become bacteriologically negative much sooner than with the polar lepromatous leprosy form. Similarly, the tuberculoid leprosy (TT) form of the disease has been divided into polar and subpolar (TTp and TTs), the subpolar form designating those patients who have developed tuberculoid leprosy on a secondary basis, an upgrading from their previous borderline form.[5]

Patients with lepromatous leprosy present with a large number of symmetrically distributed, cutaneous lesions, which may include macules, papules, infiltrated plaques, nodules (known as lepromas), or edematous, diffusely infiltrated skin. Lesions may vary from a few millimeters in size to several centimeters, be skin-colored, erythematous, or hypopigmented, and tend to localize in the cooler areas of the body. Infiltration of the earlobes is characteristic. Loss of hair may occur from the scalp, eyebrows, and eyelashes. The latter two are particularly characteristic. Nodular infiltration of the face, particularly around the orbits, may result in the grotesque leonine facies. Histological examination of lesions reveals granulomas composed of numerous foam cells stuffed with acid-fast bacilli.

In contrast, patients with tuberculoid leprosy typically present with one or a few asymmetric, erythematous or hypopigmented plaques, from a few centimeters to several decimeters in diameter. These tend to be thicker at the periphery than in the center, forming a platelike topography. Complete central clearing may occur. Dyspigmentation is common, particularly in people with darker skin color. Significant nerve involvement with anesthesia is the rule in this form, often corresponding to the nerve supplying the area of involved skin. Histologically, acid-fast bacilli are absent to very rare. The dermis may contain a few to numerous epithelioid granulomas with mantles of lymphocytes. Infiltration and destruction of small cutaneous nerves is a prominent feature.

The clinical features of borderline leprosy are intermediate between lepromatous and tuberculoid. Lesions resembling those in lepromatous leprosy appear approximately equal in number to those resembling tuberculoid leprosy. Lesions are numerous but countable, bilateral, but not symmetric. Pathologically, nerves are infiltrated but not destroyed, and acid-fast bacilli are easily seen.

Borderline lepromatous leprosy is characterized by lesions resembling those found in both lepromatous and tuberculoid leprosy, but with the lepromatous lesions predominating. Similarly, borderline tuberculoid leprosy consists primarily of up to 10 asymmetric tuberculoid plaques surrounded by satellite nodules, resembling those seen in lepromatous leprosy. Both represent intermediate transitional forms—both clinically and histologically—between borderline and lepromatous or tuberculoid leprosy, respectively.

Indeterminate leprosy is recognized as a definite clinical entity, but there is no unanimity of opinion regarding its frequency, significance, and prognosis. Patients present with a single macule or a few asymmetrical macules, with alterations in color but with no change in the surface texture or consistency of the skin. The peripheral nerves are usually normal. Slit-skin smears are usually negative. To confirm the diagnosis, sensory impairment or histological evidence of acid-fast bacilli or infiltrate must be present selectively in a nerve bundle in the dermis. Thermal sensibility may be lost earlier than tactile sensibility.[16] Indeterminate leprosy has a variable course: in approximately 75% of patients, the disease remits spontaneously; the remainder progress to one of the established forms of the disease.[14]

Primary neuritic leprosy is increasingly being recognized as a clinical form of presentation. Most will be of the paucibacillary type. A lepromin test, the number of nerves affected, and nerve biopsy may all give some indication of the correct classification, but further research is needed to provide reliable clinical indicators for correct classification of patients with primary neuritic leprosy within the Ridley-Jopling system.[16]

Skin biopsies from anesthetic areas may fail to show histological changes suggestive of leprosy. Cutaneous nerve biopsy (a simple office procedure discussed above) can be performed for both histopathological examination and for acid-fast bacilli staining. This technique yields surprisingly good results.[24]

TREATMENT

The treatment of leprosy varies considerably depending on the number of bacilli present and whether reactional states are present. WHO has recommended standard treatments for each type of leprosy (Figure 14-13).

Paucibacillary Leprosy

The 1988 WHO recommendations for the standard treatment of paucibacillary leprosy are as follows[16]:

- Rifampin 600 mg (450 mg for patients who weigh < 35 kg), once per month for 6 months (10 mg/kg in children[17]).
- Dapsone 100 mg daily for 6 months (1–2 mg/kg in children[17]).

The administration of rifampin should be fully supervised; on the other hand, dapsone may be given unsupervised. Relapses, which need to be distinguished clinically from delayed reversal reactions by slit-skin smear or biopsy, should be retreated with a 6-month course of the multidrug regimen outlined below.

Multibacillary Leprosy

The 1988 WHO recommendations for the standard treatment of multibacillary leprosy are as follows[16]:

- Rifampin 600 mg once per month, supervised (10 mg/kg in children[17]).
- Dapsone 100 mg daily, self-administered (1–2 mg/kg in children[17]).
- Clofazimine 300 mg once per month, supervised, and 50 mg daily, self-administered (1–2 mg/kg in children for both the monthly and daily doses[17]).

This treatment should be continued for at least 2 years, and, wherever possible, up to smear negativity. In multibacillary leprosy, rifampin should *never* be used alone or in combination with dapsone without a third bactericidal drug because of the high prevalence of dapsone resistance and the high risk of the development of rifampin resistance.

The addition of monthly supervised doses of ethionamide or prothionamide to this regimen is not recommended by WHO, as the triple-drug therapy is deemed adequate. Where clofazimine pigmentation has been objectionable, clofazimine has been replaced by daily thioamide (either ethionamide or prothionamide). However, this substitution is not recommended by WHO unless absolutely necessary, because it is now clear that the recommended daily dose of 50 mg is well accepted by patients and has a marked influence on the frequency and severity of reactional states.[16] Ethionamide and prothionamide can have serious hepatotoxic side effects, particularly when administered with rifampin. Both have poor gastrointestinal tolerance as well.

The Most Potent Antileprosy Drugs

Rifampin

Rifampin is by far the most potent drug against *M leprae*. A single dose of 20 mg/kg was shown (by the proportional bactericidal test method) to kill about 99% of the viable leprosy bacilli in the mouse footpad, while single, 600-mg doses of the drug given to previously untreated multibacillary patients rendered the bacilli harvested from biopsies taken 4 days later noninfectious for mice, suggesting that such a dose had killed at least 99% of the viable *M leprae*.[29] Rifampin induces the metabolism of dapsone, but in the usual clinical setting this is of little importance.[30]

Dapsone

Dapsone is a sulfonamide analog of *p*-aminobenzoic acid (PABA) that inhibits *M leprae*'s de novo synthesis of folic acid. The drug is essentially bacteriostatic. It is metabolized in the liver and excreted, as metabolites, in the urine. It is well absorbed in the gastrointestinal tract and well tolerated. Dapsone's mean half-life is 28 hours in human plasma. The predominant side effect is hemolytic anemia (especially with glucose-6-phosphate dehydrogenase deficiency). Another side effect, the dapsone syndrome, is a rare clinical syndrome that usually develops within 6 weeks of the start of therapy and consists of exfoliative dermatitis, hepatosplenomegaly, fever, generalized lymphadenopathy, and hepatitis. Agranulocytosis is occasionally seen.[30]

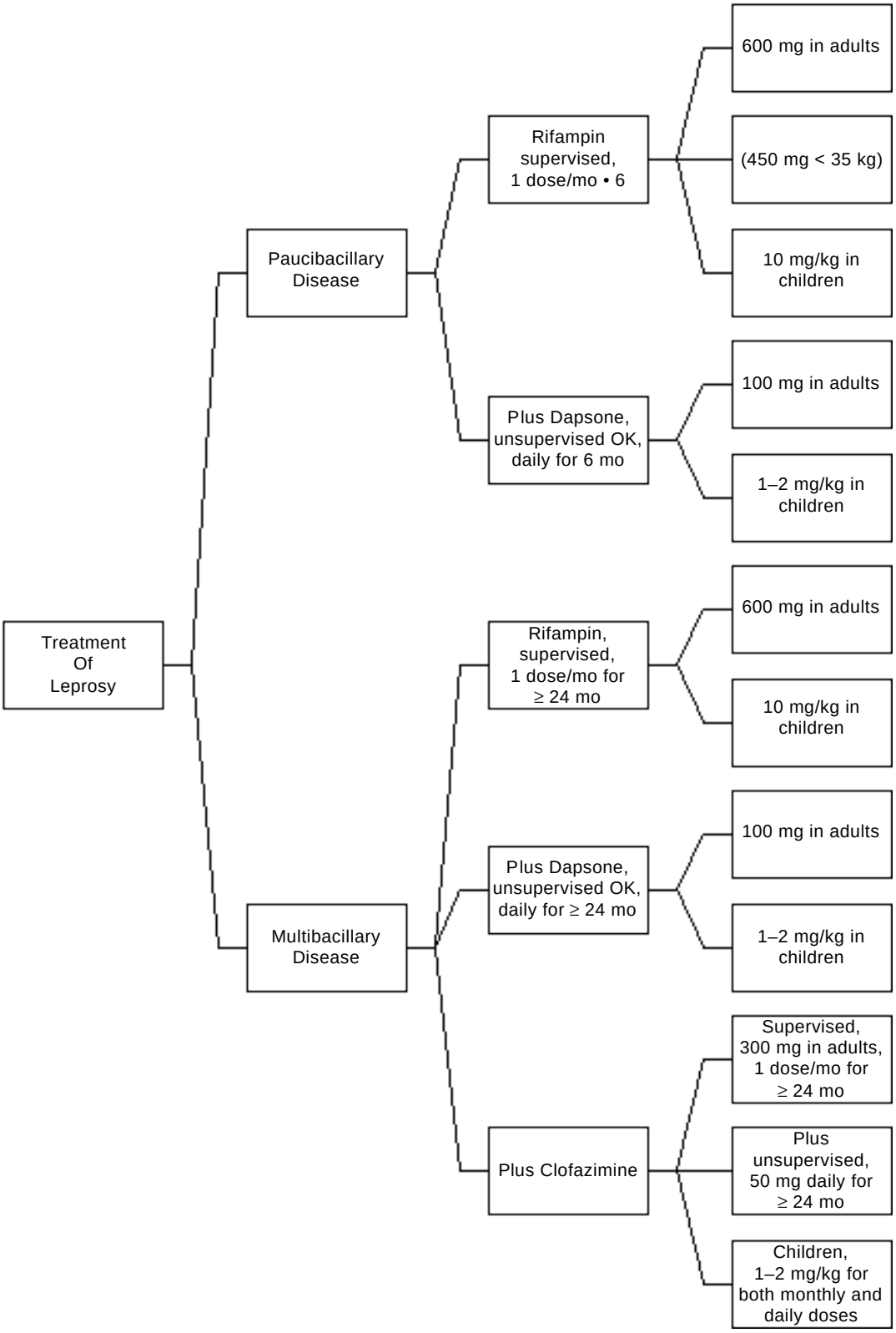

Fig. 14-13. World Health Organization guidelines for the treatment of uncomplicated leprosy. Data source: WHO Expert Committee on Leprosy. *World Health Organization Technical Report Series 768*. 6th report. Geneva, Switzerland: World Health Organization; 1988.

Clofazimine

Clofazimine is the third-most-potent antileprous drug, and has both antibacterial and anti-inflammatory effects. Its mechanism of action is not known. The drug has a complex pattern of distribution in the body, with high concentrations found in the reticuloendothelial system, the subcutaneous fat, and in the distal small bowel at the site of absorption. The half-life for elimination is estimated to be 3 months. The most dramatic side effect is dose-related skin pigmentation caused by drug accumulation (Figure 14-14). Gastrointestinal toxicity is caused by deposition of drug crystals in the distal small bowel and draining mesenteric lymph nodes.[30]

Ethionamide and Prothionamide

Ethionamide and prothionamide are essentially identical in their effects and toxicities. Ethionamide is bactericidal in the mouse footpad system and has been used in leprosy treatment for more than 20 years. It is metabolized in the liver and excreted in the urine, with a mean half-life of 3 hours. A dose of 250 to 500 mg/d is used in adults. These drugs are hepatotoxic, but when used alone rarely present a problem. When combined with rifampin, another hepatotoxic drug, the toxicities are additive. Because bacterial resistance may develop within a few years of treatment, combination therapy is mandatory.[26]

OK to print

Fig. 14-14. This patient with advanced lepromatous leprosy demonstrates significant dyspigmentation secondary to clofazimine accumulation within the lesions. Note the mild leonine facies, ear and nose deformities, and symmetry of the facial lesions.

Thalidomide

Thalidomide, a sedative-hypnotic widely used between 1957 and 1961, caused severe and characteristic fetal malformations (phocomelia) when taken by pregnant women between days 35 and 50 after the last normal menstrual period. In 1965, it was shown to be very effective in cases of erythema nodosum leprosum reactions and is now the drug of choice in men and nonfertile women. Thalidomide appears to inhibit de novo synthesis of IgM antibodies and to inhibit neutrophil chemotaxis. It has no antibacterial effect whatsoever. It is metabolized in the blood and excreted in the urine. Its half-life is 3.5 hours. Other than embryopathy, the only other significant side effect is a peripheral neuropathy.[30] Minor side effects, which are often transient, include dry mouth, rash, and constipation. Thalidomide is now supplied only through national governments that will indemnify the manufacturer (Chemie Grunenthal GmbH, Postfach 129, Zweifallerstrasse 24, 5190 Stolberg/Reinland, Federal Republic of Germany) against litigation[31] and is indicated only for Type 2 reactions (ie, erythema nodosum leprosum).[32]

Drug Resistance

Extensive evidence shows that the emergence of secondary resistance of *M leprae* to dapsone is a worldwide phenomenon, occurring in as many as 40% of treated multibacillary patients in some areas. They are resistant to high or intermediate levels of the drug. During the 1980s, primary dapsone resistance was found in up to 70% of newly detected, previously untreated patients. Most primary resistant strains of *M leprae* have been shown to be resistant to low or intermediate levels of dapsone.[16]

From data collected during the 1980s, it has become clear that when rifampin is used alone, secondary resistance develops easily and rapidly in multibacillary patients with leprosy. No primary resistance is known at present.

Clofazimine resistance is unknown or unconfirmed.

Secondary resistance to ethionamide has been demonstrated in patients treated with ethionamide

alone. Resistant strains of *M leprae* have also shown cross-resistance to prothionamide, thiacetazone, and thiambutosine.

Microbial Persistence

Viable, fully drug-susceptible *M leprae* that are able to survive for many years in patients with lepromatous leprosy, despite the presence of bactericidal concentration of an antileprosy drug, are termed *persisters*. They have been detected in about 10% of all biopsy specimens from patients with lepromatous leprosy who are receiving multidrug regimens containing rifampin—irrespective of the regimen or duration of treatment. It therefore seems likely that none of the existing drugs, used alone or in combination, greatly affects the occurrence of persisters.[33]

No clear relationship has yet been established between the existence of persisting organisms and the occurrence of relapses, and accumulating evidence from clinical trials is beginning to suggest that persisters may not pose a serious threat of relapse in patients who complete multidrug therapy, at least as far as early relapses are concerned. The rate of relapses following multidrug therapy in paucibacillary cases is about 1%, for multibacillary cases about 0.2%.[33]

Promising New Drugs

The quinolones pefloxacin and ofloxacin act by inhibiting DNA synthesis during bacterial replication, probably by interfering with DNA gyrase (topoisomerase) activity. Several rifampin derivatives, ansamycins, have shown antilepromatous activity up to 7-fold greater than rifampin. Like rifampin, however, they are very expensive.[34]

Minocycline has been shown to be much more bactericidal for *M leprae* than any other drug except rifampin. Its high lipid solubility may allow it to penetrate the outer capsule and cell wall. It apparently has additive effects when used in combination with dapsone and rifampin.[34]

Streptomycin is bactericidal and is synergistic with rifampin, even when given once per month.

Deoxyfructo-5-hydroxytryptamine (DF5-HT) has shown an ability to clear bacilli faster than dapsone, perhaps due to an immunostimulating effect.[34]

Investigational work is being done on clofazimine derivatives, including long-acting dapsone injections, macrolides, and pyrazinamide, among others.[34]

COMPLICATIONS: THE REACTIONAL STATES

Were it not for its various reactional states, which represent alterations in host immunity, leprosy would be considered a rather straightforward bacterial disease with a "cookbook" approach to therapy. Fortunately, however, the reactional states that are the source of so much difficulty—for healthcare providers as well as for patients—have also stimulated significant research into leprosy and the immune system. Currently, there are four well-recognized reactional states: (1) reversal reaction, also called Type 1; (2) erythema nodosum leprosum, also called Type 2; (3) downgrading reaction; and (4) Lucio's phenomenon (Figure 14-15). All reaction states are uncommon in children with leprosy. In a series of 132 cases of leprosy in children from northern India, 4 patients (3%) had reversal reactions, 2 (1.5%) had downgrading reactions, and only 1 (0.7%) had a Type 2, or erythema nodosum leprosum, reaction.[19]

Reversal Reaction

Reversal reactions, also called Type 1 reactions, occur in patients with unstable borderline disease in the Ridley-Jopling classification scheme (ie, BT, BB, BL), who experience a rapid increase in specific cell-mediated immunity often brought on by either treatment or improved nutrition. This reaction is called a *reversal* because patients with borderline disease typically worsen slowly in the opposite direction (ie, toward the lepromatous end of the spectrum), but in this reaction, the patients are improving slightly (ie, the downward spiral of the natural course of the disease is reversing).

The reversal reaction is a Type IV hypersensitivity reaction, in which the host has an increased immune response against the antigens of *M leprae*. Thus, in terms of the killing and clearing of bacteria, this reaction is beneficial. However, the inflammation, particularly in nerve tissue, may be devastating. It is important to warn patients with borderline disease ahead of time about reversal reactions; otherwise, when the inflammation occurs, the patient may think the therapy is not working, lose confidence in the physician, and risk permanent disability from neglect.[32]

Most commonly, reversal reactions occur during the first 6 months of treatment, particularly in pa-

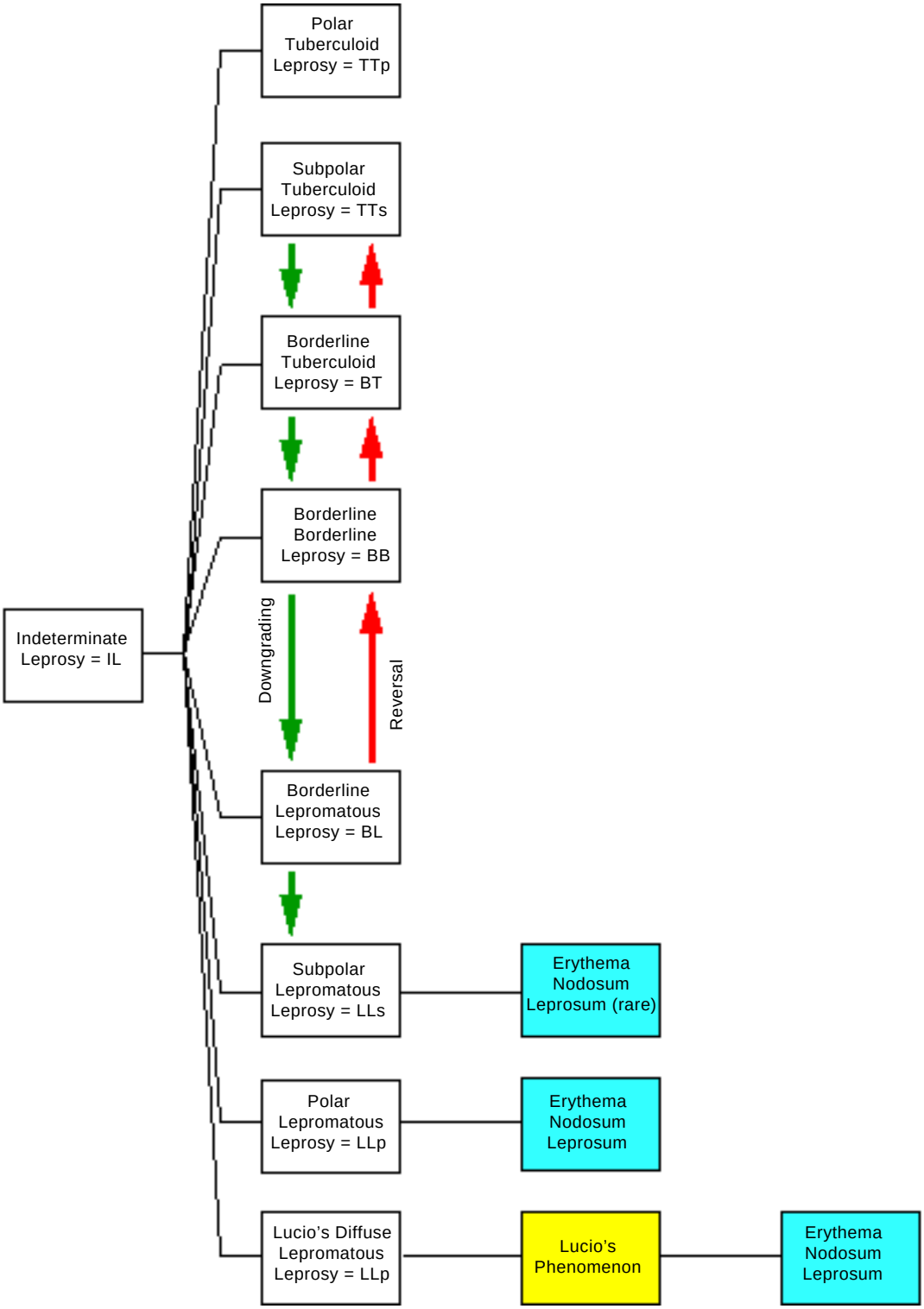

Fig. 14-15. The possible reactional states in leprosy: reversal reaction, also called Type 1 (red); erythema nodosum leprosum, also called Type 2 (blue); downgrading reaction (green); and Lucio's phenomenon (yellow). Note that erythema nodosum leprosum can occur via three pathways.

tients with borderline borderline (BB) and borderline tuberculoid (BT) leprosy. The normal progression in clinical classification in reversal reactions is

LLs —> BL —> BB —> BT —> TTs

The cardinal signs of a reversal reaction are the rapid development of erythema, warmth, and swelling in one or several preexisting clinical lesions (Figure 14-16). Nerve involvement, seen clinically as pain, swelling, and motor or sensory disturbances, is common and can constitute a medical emergency. Delay of treatment for even 2 days may result in severe adverse effects (eg, paralysis of the ulnar nerve, causing claw hand; of the lateral popliteal nerve, causing foot drop; and of the facial nerve, causing facial palsy). In the field or clinic, the following simple test of nerve function[32] can rapidly be carried out by checking

OK to print

Fig. 14-16. Type 1 reversal reaction. This Filipino woman developed a rapid increase in erythema, warmth, and swelling in her preexisting lesions of borderline lepromatous leprosy.

- the eyes for complete closure and normal blinking;
- the hand for loss of sensation, using nylon bristles or a ballpoint pen, and for loss of strength by abduction of the fifth finger and opposition of the thumb against firm pressure; and
- the foot for loss of sensation as above, and for loss of strength by dorsiflexion of the foot against firm pressure.

Systemic symptoms such as fever or malaise are unusual. Associated findings may include edema of the hands, feet, and face in any combination. Rarely, new lesions with tuberculoid characteristics may develop and cause confusion with a downgrading reaction. However, histology and lepromin testing are confirmatory.[5]

Histological Findings

Histological findings show a shift of classification toward the tuberculoid end of the spectrum. Edema is present; the bacilli are reduced; and increased numbers of defensive cells such as lymphocytes, epithelioid cells, and giant cells are seen.

Treatment

Systemic corticosteroids are very effective in reducing the edema and inflammation in reversal reactions and, thus, are most helpful in preventing nerve damage (Figure 14-17). Initial doses of prednisone, 40 to 80 mg/d for 5 to 7 days, may alleviate neuritis and edema. Tapering must be done slowly: the dose must not be reduced by more than 5 mg once or twice per week. Treatment with prednisone for 3 to 6 months is necessary in most cases and is definitely associated with decreased frequency and severity of disabilities and deformities as compared to shorter courses of prednisone.[35]

Thalidomide is not useful in the treatment of reversal reactions. Clofazimine's usefulness has not been clearly demonstrated for acute reversal reactions, in contrast to its usefulness in erythema nodosum leprosum, but clofazimine does play a role in chronic reversal reactions, where it may be steroid sparing. When used, clofazimine is begun at 100 mg three times daily for 6 weeks; then, if steroid sparing, reducing the dose to twice daily for several months, then daily for a few more months.[35]

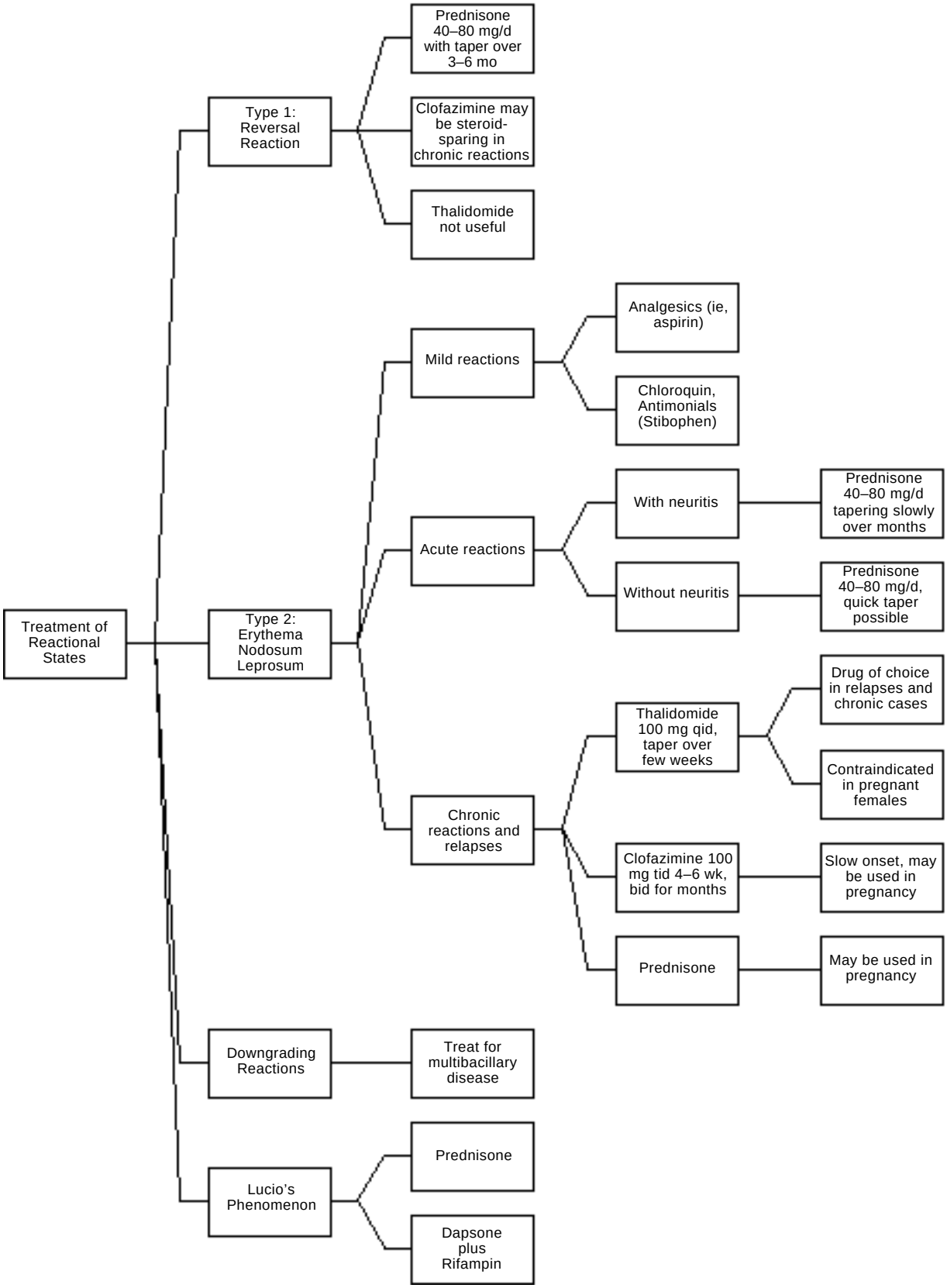

Fig. 14-17. Treatment algorithm for reactional states in leprosy **.**

Erythema Nodosum Leprosum

Erythema nodosum leprosum, also called the Type 2 reaction, is named for its most prominent clinical finding: an eruption of tender, red nodules. It is an immune complex disease, a Type III hypersensitivity reaction, and occurs almost exclusively in patients with lepromatous leprosy (LLp and LLs), and only occasionally in patients with borderline leprosy (BL). Antigens of *M leprae* and antibodies form immune complexes with complement, which precipitate in the tissues of the skin, blood vessel walls, nerves, and other organs; these precipitates attract neutrophils, which further damage the tissues. Predisposing factors include infections (eg, malaria, filaria, bacterial infections), trauma, surgery, physical or psychological stress, immunizations or vaccinations, pregnancy, parturition, ingestion of potassium iodide, and antileprous therapy (ie, dapsone, thiacetazone, rifampin).[5]

Clinically, the preexisting lesions of leprosy remain unchanged. However, new crops of brightly erythematous, painful nodules may come and go. Fever and malaise are common. The reaction tends to occur late in treatment, unlike reversal reactions, and often at a time when the skin lesions are quiescent and most of the bacteria are granular on the morphologic index. The skin lesions alone are also known as erythema nodosum leprosum. The lesions tend to be small, variably sized, slightly raised, tender nodules and plaques, which are brightly erythematous, warm, and blanchable. In contrast to classic erythema nodosum, the lesions of erythema nodosum leprosum last only 2 to 3 days, often resolving with hyperpigmented residua. They can be very numerous and widely disseminated. The scalp and the intertriginous areas tend to be spared. The lesions leave a blue stain when they regress. Associated features of Type 2 reactions include nerve pain, periosteal pain (especially in the tibia), myalgias or myositis or both, arthralgias or arthritis or both, rhinitis, epistaxis, acute iritis, dactylitis, lymphadenitis (especially the femoral chain), acute epididymo-orchitis, and proteinuria. Although nerve involvement occurs both in reversal and Type 2 reactions, it progresses much more slowly in the latter. If left untreated, however, it may still produce severe and extensive nerve damage. Edema of the hands and feet can be one of the major presenting features of erythema nodosum leprosum. If edema is present for more than a few days, stiffness and deformityof the fingers may result, hence treatment is imperative. Overall, erythema nodosum leprosum tends to be a chronic, smoldering process that often lasts for years.

In the laboratory, circulating immune complexes can be detected. Additionally, tests for antinuclear antibody and rheumatoid factor may be positive.

Histological Findings

Existing leprosy lesions show some edema. Erythema nodosum leprosum lesions show a leukocytoclastic vasculitis of both veins and arterioles; polymorphonuclear lymphocyte infiltrate; and scanty, fragmented bacilli.

Treatment

Mild cases of erythema nodosum leprosum may hardly be noticed and often respond to minor symptomatic care with analgesics such as aspirin. Chloroquin and antimonials such as stibophen have also been used for mild cases, but are not indicated for neuritis or chronic reactions. Stibophen is given as a 5-mL intramuscular injection on alternate days for 3 doses. A second course may be given after a 2-week interval.[32]

Treatment for more extensive or severe Type 2 reactions requires systemic corticosteroids or thalidomide.[35] Acutely, prednisone in doses of 40 to 80 mg/d is begun. In the absence of neuritis, the dosage may be tapered moderately quickly once symptoms have been suppressed. Relapse is common and the dosage needs to be individualized. Where neuritis is present (or if nerve function has been lost within the preceding 6 mo), daily corticosteroids may be necessary for months. If the daily dose remains above 30 mg of prednisone, then switching to alternate-day steroids may be helpful. However, if nerve pain returns on the "off" day, then the physician must assume that nerve damage is occurring and reinstitute daily steroids. For acute, painful, hand edema, splinting of the hands in a position of function for a few days, as well as administering prednisone, are indicated. Subsequently, physical therapy may be started to prevent stiffness and loss of function. Thalidomide has rapid onset of action, often bringing relief within 24 hours. It is steroid sparing. Consequently, it is a drug worthy of serious consideration in severe erythema nodosum leprosum.[31]

For more chronic cases or for relapses, thalidomide is the drug of first choice (except in fertile women, due to its teratogenicity). The initial dose is 100 mg four times daily, which can be tapered

within a week to 100 to 200 mg/d. Further tapering to 50 to 100 mg/d may be possible. This dosage may need to be continued for 1 to 2 months, then discontinued. If erythema nodosum leprosum recurs, treat again with thalidomide.[35]

Alternatively, clofazimine can be beneficial, not only in suppressing the reaction, but also in its antibacterial and steroid-sparing effects. Unfortunately, its onset of action is delayed for 4 to 6 weeks. Clofazimine is given 100 mg three times daily for 4 to 6 weeks, then tapered to twice daily for several more months. Gastrointestinal intolerance may force a reduction in dose to 100 mg/d. The other major side effect of clofazimine is skin darkening.[35]

Some patients may require a combination of all three medications. In select circumstances such as in the case of nerve entrapment, surgical decompression may be indicated.[35]

In pregnancy, clofazimine and steroids may be used, as well as dapsone. However, thalidomide is absolutely contraindicated. Rifampin has also been associated with fetal anomalies (in animals only)[35]; hence its use should be avoided in pregnant women.

Downgrading Reaction

Untreated patients are sometimes seen with a reaction that clinically appears similar to a reversal reaction, but who are, in fact, undergoing a downward shift in their immunity toward the lepromatous end of the spectrum. They are described as having a downgrading reaction. However, the diagnosis is difficult to make unless the patient is followed for a long period of time.

There is a shift in the Ridley and Jopling Classification system toward the lepromatous end of the spectrum, with an increase in bacilli and macrophages, and a decrease in lymphocytes, epithelioid, and giant cells.

The treatment for downgrading reactions is the same as that for multibacillary disease. Where drug-resistant organisms are suspected, additional measures (eg, the administration of additional and more toxic antibiotics) may be necessary.

Lucio's Phenomenon

The fourth state, Lucio's phenomenon, is a rare type of acute, reactional leprosy. This state occurs only in patients with Lucio's leprosy, the rare, diffuse, nonnodular form of lepromatous leprosy that is seen in Mexico and Central America. Lucio's phenomenon is unique in that it occurs only in untreated patients. The reaction is characterized by crops of painful, tender, red macules that become purpuric, then necrotic, and finally ulcerative. The lesions eventually heal with atrophic, stellate scars. Patients are usually afebrile. The extremities are involved predominantly.

The lesions are essentially due to a necrotizing vasculitis that is caused by circulating immune complexes including mixed cryoglobulins.[36] Apparently, patients with Lucio's phenomenon have a deficient cell-mediated defense mechanism that permits unhindered multiplication of bacilli and production of circulating bacterial antigen. Production of antibodies by an active humoral immune system then results in vasculitis, infarction, and skin necrosis.

Histological findings include ischemic epidermal necrosis; necrotizing vasculitis of small blood vessels in the upper dermis; severe, focal, endothelial proliferation of middermal vessels; and large numbers of bacilli in the endothelial cells.[5]

Treatment with corticosteroids or dapsone combined with rifampin is beneficial. Thalidomide is of no value.[5] Many of these patients will develop the Type 2 reaction, erythema nodosum leprosum, once definitive antilepromatous therapy is begun.

VACCINATION

Information on the value of Bacille bilié de Calmette-Guérin (BCG) vaccination against leprosy is available from five large field studies conducted by WHO[16]: the protective effect of BCG was generally high (80%) in Uganda, moderate (45%–55%) in Malawi and Papua New Guinea, and low (20%–30%) in Burma and India. In all these studies, the observed protective effect of BCG was primarily against paucibacillary leprosy. Currently, studies are underway to assess the use of vaccines of killed *M leprae* combined with BCG versus BCG alone in 120,000 subjects in Malawi.[16]

The goal is to produce a genetically engineered, safe, potent leprosy vaccine consisting of highly immunogenic BCG that contains the appropriate genes of *M leprae*. This approach may allow those antigens associated with a protective immune response to be expressed.[14]

LEPROSY AND ACQUIRED IMMUNODEFICIENCY SYNDROME

Because leprosy is associated with a defect in cell-mediated immunity, and because tuberculosis is now seen as a presenting sign of acquired immunodeficiency syndrome (AIDS), will leprosy also be seen as a presenting sign of AIDS, especially because AIDS suppresses cell-mediated immunity?

The only data on this question have been reported from rural Zambia. This study[37] included all patients with tuberculosis and leprosy at the Chikankata Salvation Army Hospital who were seen from October to December 1987. Of 27 patients with leprosy, 18 had new cases. Of those 18 new patients, 6 (33%) also had antibodies to human immunodeficiency virus (HIV), as detected by the Wellcozyme VK51 (ELISA) test. Positive results were confirmed on a second date and then reconfirmed using other serologic testing. Because the serologic prevalence of infection with HIV was significantly higher than that found in blood donors and surgical patients, and because the patients with leprosy tended to have more serious symptoms such as paralysis or neuritis, rather than a skin lesion, this study suggests that AIDS may predispose to leprosy. For comparison, 50% of the confirmed cases of tuberculosis showed evidence of HIV infection.

SUMMARY

Leprosy is an infectious disease caused by the bacterium *Mycobacterium leprae*. The major source of infection is patients already infected with the most severe form of the disease, lepromatous leprosy, who shed millions of organisms per day in their nasal secretions. Acquisition of the disease requires prolonged contact with patients with lepromatous leprosy, and fewer than 1% of exposed individuals will ever develop the disease. Of those who do, 75% will heal spontaneously. Thus, only about 0.25% of exposed individuals ever develop clinical disease, and then many months or years after exposure.

The disease can take a wide variety of forms, depending on the immune status of the patient. Initially, no lesions or nondiagnostic hypopigmented macules are seen. This stage is known as indeterminate leprosy. Over time, 25% of these patients will progress to a more serious form of the disease. Those with poor immunity tend to develop the widely disseminated, symmetric, infiltrated papules and plaques of lepromatous leprosy, the skin lesions of which teem with acid-fast organisms. The involvement of the internal organs may be substantial in such patients. Patients with good immunity tend to develop one or a few asymmetric, indurated plaques, with a tendency for central clearing associated with significant nerve involvement. Other patients with moderate immunity develop an intermediate form—between lepromatous and tuberculoid leprosy—known as borderline leprosy. Patients whose disease leans more toward lepromatous leprosy than tuberculoid are said to have borderline lepromatous leprosy; whereas those whose disease leans more toward the tuberculoid side are said to have borderline tuberculoid leprosy.

Diagnosis is made on the basis of clinical findings including characteristic skin lesions, nerve involvement with anesthesia or nerve enlargement, and demonstration of acid-fast organisms in biopsies, nasal secretions, or from slit-skin preparations.

Currently, for treatment purposes, paucibacillary disease is defined as being smear negative, whereas multibacillary disease is defined as being smear positive. WHO treatment guidelines for both paucibacillary and multibacillary disease should be followed exactly and continued for a minimum of 2 years and until the smear is negative. Deviating from the guidelines may lead to antibiotic-resistant organisms.

Reactional states are frequent in leprosy. They constitute fluctuations in the patient's immune status that may be deleterious to the patient's health and lead to life- and limb-threatening complications. There are four reactional states. Type 1 reactions, also called reversal reactions, occur early in treatment in patients with unstable borderline disease of the borderline tuberculoid (BT), borderline borderline (BB), or borderline lepromatous (BL) types. Here, because of improving immunity, inflammatory reactions develop in preexisting lesions and may result in nerve paralysis. Reversal reactions constitute a medical emergency. Prednisone continues to be the initial drug of choice. The Type 2 reaction, also called erythema nodosum leprosum, is a Type III immune-complex hypersensitivity reaction that occurs primarily in long-stand-

ing lepromatous leprosy of the lepromatous lepromatous polar or subpolar (LLp or LLs) forms, or, rarely, in borderline lepromatous (BL) disease. Systemic symptoms (eg, fever and malaise, neuritis, myalgias and arthralgias) accompany the bright-red crops of new, painful skin nodules. The third reactional state is called downgrading, in which the patient slips toward the lepromatous end of the spectrum. Downgrading reactions are difficult to diagnose, appear similar to reversal reactions, and are treated for ongoing or drug-resistant multibacillary disease. The fourth reactional state, Lucio's phenomenon, occurs only in patients who have the diffuse lepromatous leprosy known as Lucio's leprosy. The reaction, a necrotizing cutaneous vasculitis, occurs only in untreated patients.

Medical officers need to understand that leprosy does not constitute a health threat to most troops. Prolonged, intimate contact with untreated individuals with lepromatous leprosy is necessary to transmit the disease, and more than 99% of all exposed individuals will resist infection. Such conditions are present in underdeveloped areas of the world, and may certainly be exacerbated by conditions of war (eg, famine, confinement, internment in concentration camps). Despite these well-established medical facts, the popular concept of leprosy—a horrible, disfiguring, infectious disease sent as a punishment from God—continues to terrify the uninformed.

REFERENCES

1. Klingmüeller V. Die lepra. In: Jadassohn J, ed. *Zehnter Band, Zweiter Teil, Handbuch der Haut- und Geschlechtskrankheiten*. Berlin: Verlag von Julius Springer; 1930.

2. Doull JA. Leprosy. In: Hoff EC, ed. *Communicable Diseases Transmitted Through Contact or by Unknown Means*. In: Coates JB Jr, ed. *Preventive Medicine in World War II*. Vol 5. Washington, DC: Medical Department, US Army, Office of The Surgeon General; 1960: 25–35.

3. Leviticus 13:12–13 (New International Version).

4. Unna PG. An exemplary instance of faulty scholarship. *Am J Dermatopathol*. 1983;5:569–574.

5. Jopling WH, McDougall AC. *Handbook of Leprosy*. 4th ed. Oxford, England: Heinemann Professional Publishing; 1988.

6. Skinsnes OK, Chang PH. Understanding leprosy in ancient China. *Int J Lep*. 1985;53:289–307.

7. Ell SR. Leprosy and social class in the Middle Ages. *Int J Lep*. 1986;54:300–305.

8. Ell SR. Plague and leprosy in the Middle Ages: A paradoxical cross-immunity? *Int J Lep*. 1987;55:345–350.

9. Ell SR. Three times, three places, three authors, and one perspective on leprosy in medieval and early modern Europe. *Int J Lep*. 1989;57:825–833.

10. Dayal R, Hashmi NA, Mathur PP, Prasad R. Leprosy in childhood. *Ind Ped*. 1990;27:170–180.

11. Sehgal VN, Joginder. Slit-skin smear in leprosy. *Int J Dermatol*. 1990;29:9–16.

12. Trautman JR. A brief history of Hansen's disease. *The Star*. 1990;50: 3–5, 15.

13. Noordeen SK. Leprosy control through multidrug therapy (MDT). *Bull WHO*. 1991;69:263–269.

14. Hastings RC, Gillis TP, Krahenbuhl JL, Franzblau SG. Leprosy. *Clin Microbiol Rev*. 1988;1:330–348.

15. Allen AM. *Skin diseases in Vietnam, 1965–72*. In: Ognibene AJ, ed. *Internal Medicine in Vietnam*. Vol 1. Washington, DC: Medical Department, US Army, Office of The Surgeon General, and Center of Military History; 1977.

16. WHO Expert Committee on Leprosy. *World Health Organization Technical Report Series 768*. 6th report. Geneva, Switzerland: World Health Organization; 1988.

17. Sehgal VN, Srivastava G. Leprosy in children. *Int J Dermatol*. 1987;26:557–566.

18. Brubaker ML, Meyers MW, Bourland J. Leprosy in children one year of age and under. *Int J Lep*. 1985;53:517–523.

19. Kaur I, Kaur S, Sharma VK, Kumar B. Childhood leprosy in northern India. *Ped Dermatol*. 1991;8:21–24.

20. Sehgal VN, Joginder, Sharma VK. Immunology of leprosy: A comprehensive survey. *Int J Dermatol*. 1989;28:574–584.

21. Centers for Disease Control. Update: Universal precautions for prevention of transmission of human immunodeficiency virus, hepatitis B virus, and other bloodborne pathogens in health-care settings. *MMWR*. 1988;37:377–382.

22. Pattyn SR. Minimal requirements for the laboratory diagnosis of leprosy in field conditions. *Acta Leprol*. 1983;1:33–40.

23. Ridley DS. Therapeutic trials in leprosy using serial biopsies. *Leprosy Review*. 1958;29:45–52.

24. Jacob M, Mathai R. Diagnostic efficacy of cutaneous nerve biopsy in primary neuritic leprosy. *Int J Lep*. 1988;56:56–60.

25. Sehgal VN. Clinical criteria for diagnosis of Hansen's disease. *The Star*. 1990;50:14–16.

26. Sehgal VN. Histopathology only supplements not supplants the clinical diagnosis of Hansen's disease. *The Star*. 1990;50:15–16.

27. Olivier HR. Psychiatric aspects of Hansen's disease (leprosy). *J Clin Psychiatry*. 1987;48:477–479.

28. Ridley DS. Histological classification and the immunological spectrum of leprosy. *Bull World Health Organization*. 1974;51:451–463.

29. Ellard GA. Chemotherapy of leprosy. *Br Med Bull*. 1988;44:775–790.

30. Hastings RC, Franzblau SG. Chemotherapy of leprosy. *Ann Rev Pharmacol Toxicol*. 1988;28:231–245.

31. Jakeman P, Smith WCS. Thalidomide in leprosy reactions. *Lancet*. 1994;343:432–433.

32. Sansarricq H. Technical problems related to multidrug therapy in leprosy control. *Acta Leprol.* 1989;7:59–62.

33. Baker RJ. The need for new drugs in the treatment and control of leprosy. *Int J Lep*. 1990;58:78–97.

34. Wheate HW. Management of leprosy. *Br Med Bull*. 1988;44:791–800.

35. Yoder LJ. Management of reactions in Hansen's disease. *The Star*. 1987;47:1–7.

36. Quismorio FP, Rea T, Chandor S, Levan N, Friou GJ. Lucio's phenomenon: An immune complex deposition syndrome in lepromatous leprosy. *Clin Immunol Immunopathol*. 1978;9:184–193.

37. Meeran K. Prevalence of HIV infection among patients with leprosy and tuberculosis in rural Zambia. *Br Med J*. 1989;298(6670):364–365.